
Collection of
clinical cases on
UV Active

Contents

01 Soft bone Case

UV implant embedding by using guided surgery for weak osseous tissues

Dr. Son, Hyun Rak, Director of Newton Dental Hospital

02 Case of immediate embedding after extraction of tooth in upper jaw

Comparing bone integration strength of two different implant fixtures

Dr. Woo, Yeong Hoon, Director of Millennium Yonsei Dental Clinic

03 Case of anterior teeth in upper jaw

Case on embedding immediately upon extraction of anterior teeth in upper jaw with the use of guided surgery

Dr. Jang, Jeong Rok, Director of Yeosu Moa Dental Hospital

04 UV Clinical Series

Collection of
clinical cases on

UV Active

01

Clinical Case Report
Soft bone Case

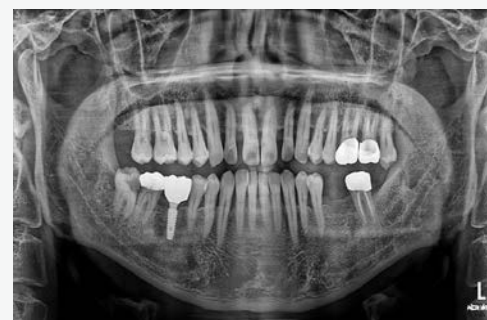UV implant embedding by using guided surgery for weak osseous tissues

Dr. Son, Hyun Rak, Director of Newton Dental Hospital

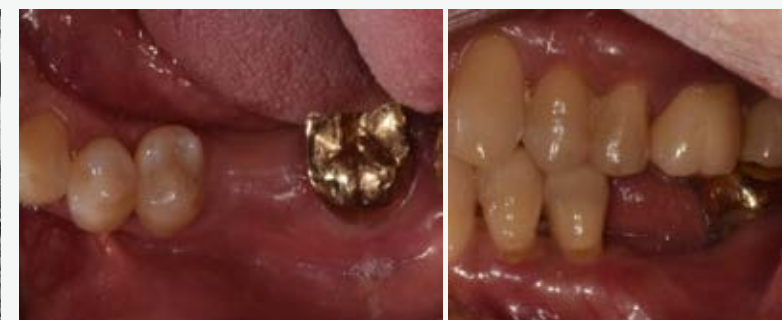55-year old male / Loss of tooth #36

- Embed #36 UF(II) Ø5.0 x 11.5mm fixture by using surgical guide

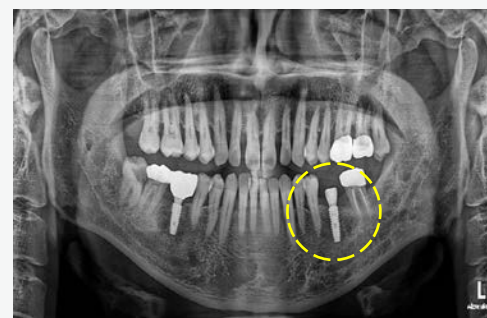
Single case of moral tooth on lower jaw without bone transplant



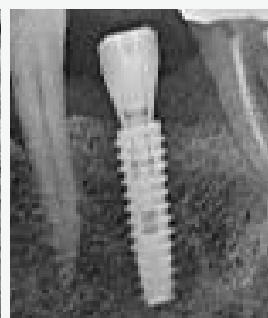Panoramic view of the loss of tooth #36 at the initial examination



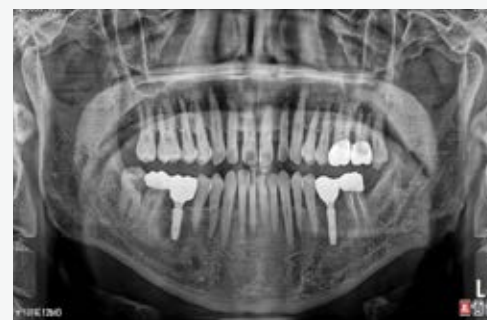Oral cavity image at the initial examination



Bind H-Scanbody after DIOnavi. surgery



Dental formula No.	Imp. Size	Bone Density	ISQ 1st OP	ISQ 4Week
#36	DIO UVØ5.0 X 11.5	D3	76	85



Panoramic view after the binding of the final prosthesis with cemented abutment

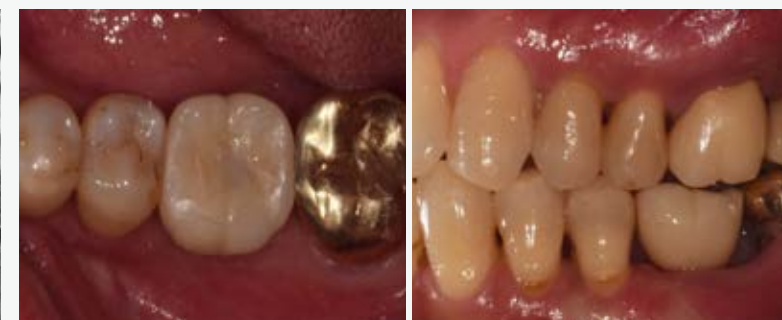

Image of the oral cavity after the binding of the final prosthesis with cemented abutment

Comparing bone integration strength of
two different implant fixtures

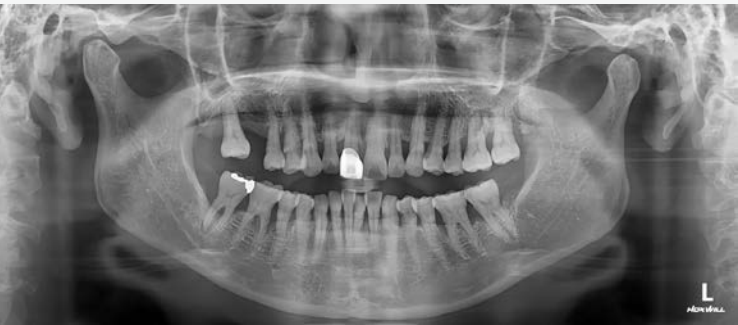Dr. Woo, Yeong Hoon, Director of Millennium Yonsei Dental Clinic

50-year old female / Generalized moderate to severe periodontitis / #16 missing, #17 and #26 mob++

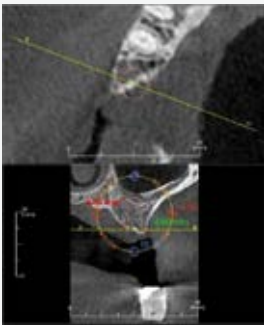
#16 was extracted 6 months ago and the patient visited the hospital due to pain and wobbling of #17

Extracted #17 due to severe periodontitis

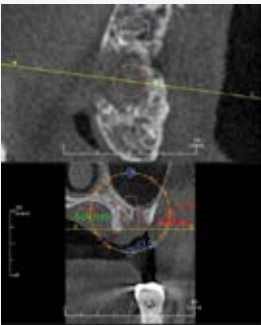
- Autologous bone transplant after 2~3mm sinus lifting with crestal approach
- Embedded with UF(II) Ø4.5x10mm HAS and UF(II) Ø5.0x10mm UV for #16 and #17, respectively
- Bone transplant with 0.25g of InterOss at the dehiscence area of #17



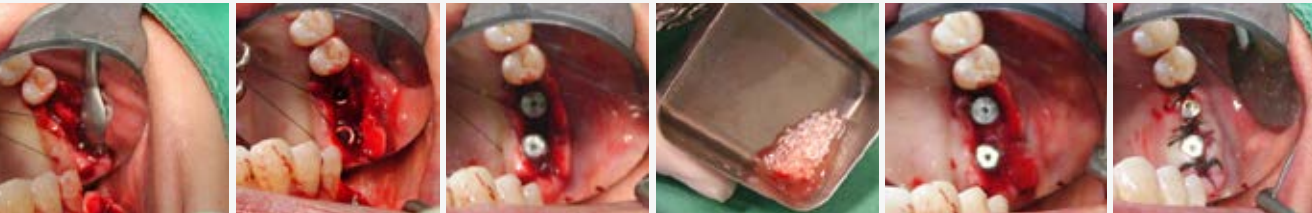
Panoramic view at the initial examination
6 months after the extraction of #16
Severe state of periodontitis in #17



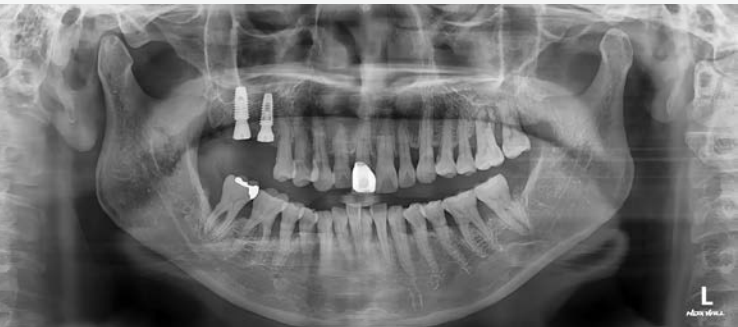#16 CT
D3-D4 bone
8mm buccal
8mm palatal



#17CT
D3-D4 bone
Buccal dehiscence
4mm buccal
8mm palatal



Bone transplant process



Panoramic view after the surgery

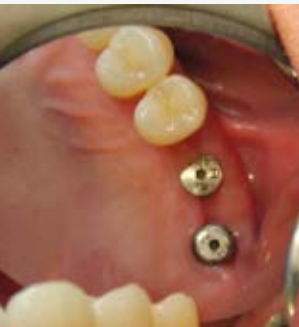

Image of oral cavity 2 months after the surgery

Dental formula No.	Size	Bone Density	Torque for embedding	OP	1Week	4Week	8Week
#16	DIO HSA Ø4.5 X 10	D3~D4	30N	80	80	80	81
#17	DIO UV Ø5.0 X 10	D3~D4	25N	73	73	75	82

HSA implant and UV implant were embedded for #16 and #17, respectively to compare the bone binding force of 2 different implants.
There was no complication other than usual edema and pain after the surgery. ISQ (DIO IDx) value of the implant was measured on the day, and 1, 4 and 8 weeks after the surgery. While the #16 implant with HSA surface processing display no major change in the ISQ value, it was possible to observe continuous improvement in ISQ values from the 4th to the 8th week for the #17 implant that underwent photo-activation for 15 minutes with UV light immediately prior to embedding. It is thought to be helpful in quick osseointegration in the area of transplant due to poor or inadequate osseous tissues.

03

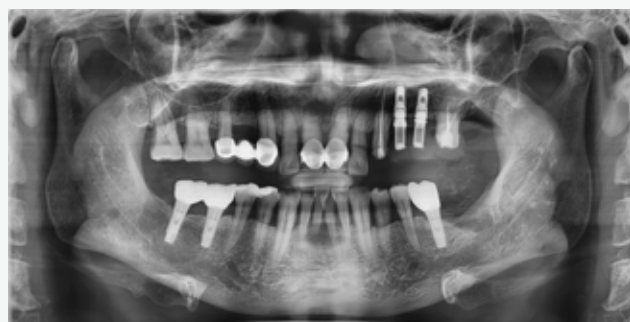Clinical Case Report
Case of anterior teeth
in the upper jaw

Case on embedding immediately upon extraction of anterior teeth in upper jaw with the use of guided surgery

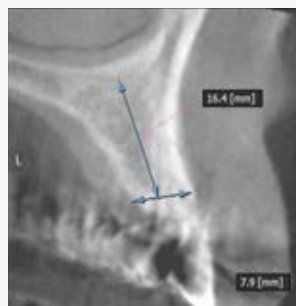Dr. Jang, Jeong Rok, Director of Yeosu Moa Dental Hospital

50-year old male / Although there was agitation in #11 and #21 since his first visit to the hospital 4 years ago, fixation and deviation were repeated with G-fix since the patient did not want treatment. Then, he eventually decided to undergo implant procedure after extraction of the corresponding teeth.

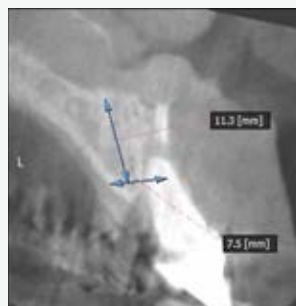Planned bone transplant and embedding of implant by using DIONavi. guide in the #12 and 22 positions after extraction of teeth #11, 12, 21 and 22.



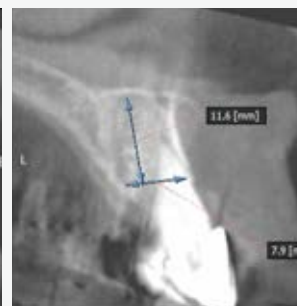
Panoramic view prior to the procedure




#12



#11



#21



#22

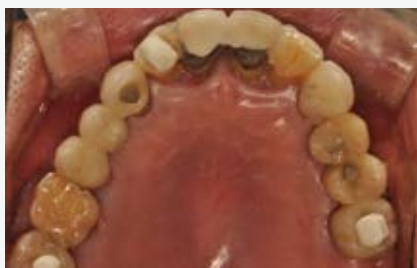
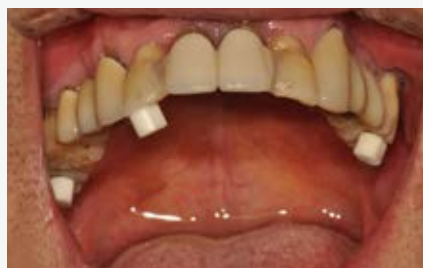
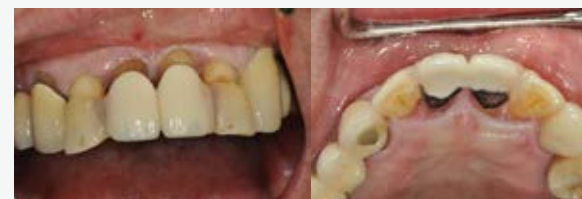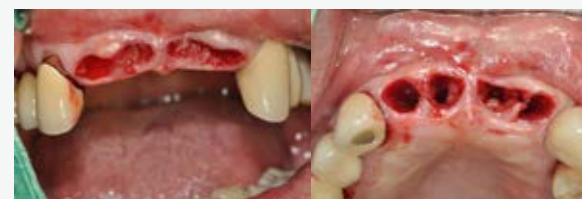Image of oral cavity prior to the procedure: Image of attachment of DIO marker due to the decision that matching CT and artifact would be difficult due to the existing prosthesis as the result of Trios scanning for the manufacturing of DIONavi guide

DIONavi. surgery process

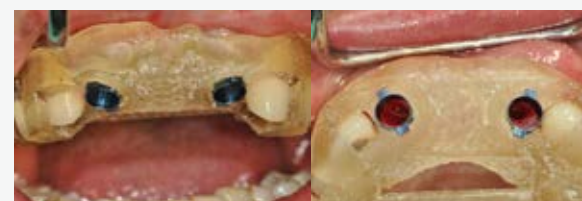01 _Prior to the surgery



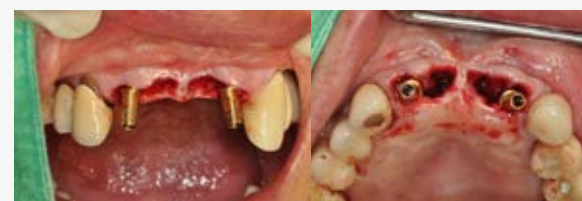02 _Tooth extraction



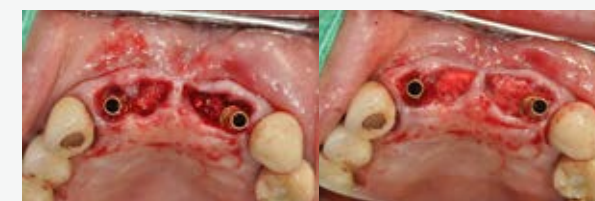03 _Attachment of guide



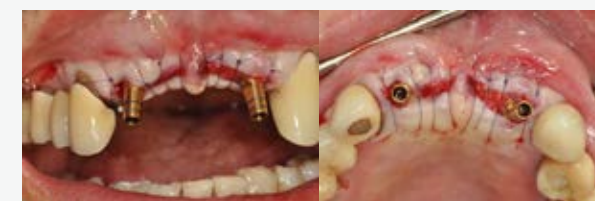04 _Binding of pre-existing abutment for immediate prosthesis



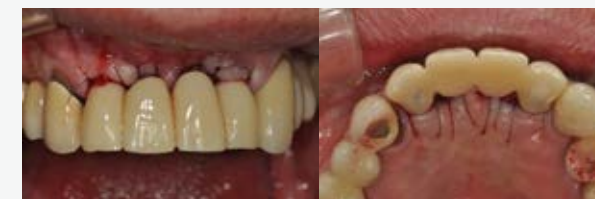05 _Heterogeneous bone transplant

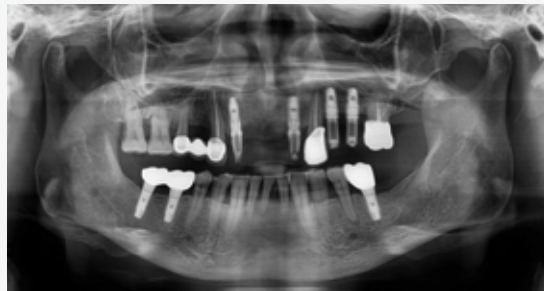


06 _Suture



07 _Attachment of temporary prosthesis





Panoramic view after the surgery

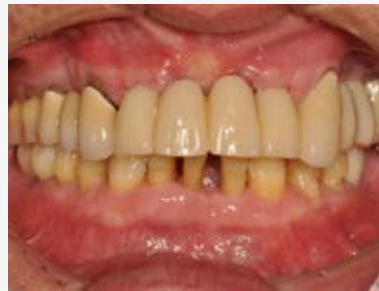
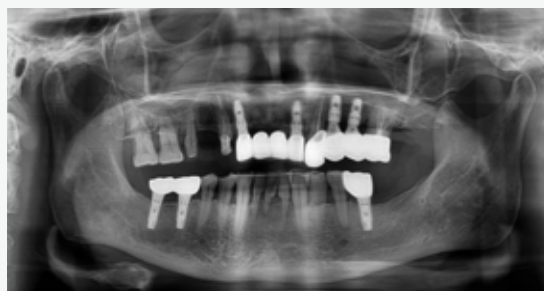
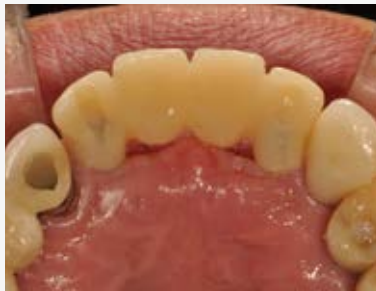Image of oral cavity after 2 weeks



Panoramic view after the final prosthesis

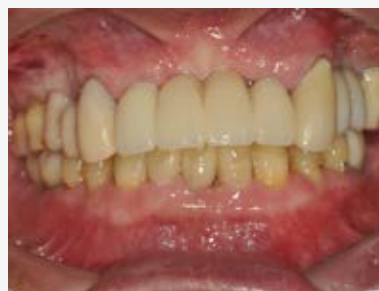
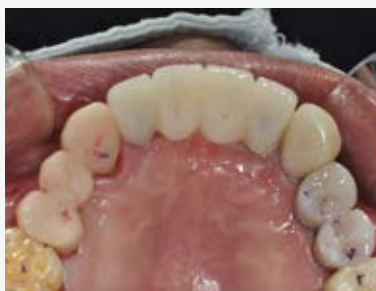
Image of oral cavity after the final prosthesis



Dental formula No.	Size	1st OP	4 months later
#12	DIO UV Ø4.0 X 11.5	72	80
#22	DIO UV Ø4.0 X 11.5	72	80

Although it was originally planned to execute final prosthesis 2 months after the UV implant procedure, it was completed 4 months later due to the personal reasons of the patient.

01) Efficacy and clinical utilization of UV Activated implant

Newton Dental Hospital Dr. Hyunlak Son
Yedam Dental Hospital Dr. Kang, Jae Seok

02) Overcome the Limitation in Surface Processing of Implant! UV Irradiation

Daejeon Sun Dental Hospital General Manager, Min-Seok Oh

I . Efficacy of UV Activated Implant

Since the development of implants the technology for processing the implant surface has been researched and developed continuously in the methods of not only increasing the physical surface area but also biological stability of the implant. However, it was discerned that biological aging phenomenon, which hinders the union of the bone and the implant occurs over time through the adhesion of organic matters such as hydrocarbon, etc. in the air onto the implant surface. Accordingly, ultraviolet (UV) ray activating implant method using photo-catalysis technology, that is used widely in general industries, has been researched continuously since several years ago in order to solve such problem.

In consideration of our society in recent years with increase in the demands and increase in more challenging implant surgeries due to rapid aging of the population, it is undeniable that general dental clinicians would find it very interesting and intriguing that with UV activated implants, it is not only possible to shorten synostosis period but also increase synostosis between the implant and the bones, which can also be used in difficult cases including those with inadequate bone density or immediate loading after tooth extraction, etc.

This paper is aimed at examining the clinical utilization of UV Activated implant, beginning with theoretical considerations of the UV Activated implant, as a means of overcoming the limitations of surface processing of implants.

1. Implant surface processing and biological aging phenomenon

Unlike the esorbable Blasting Media (RBM) surface processing in the format of physically increasing the surface area of implant through pressurized spraying of hydroxyapatite powder onto pure titanium surface of the implant, Sandblasted with Large grit and Acid etched (SLA) processing in which the surface area of the implant is increased by pressurized spraying of alumina powder along with etching of the surface with strong high temperature acid will turn the implant surface into a state that can promote osteogenesis through formation of TiO₂, that is, oxide film on the surface.




Fig.1 Martin Andersson, Department of Chemical and Biological Engineering, Applied Chemistry, Chalmers University of Technology, Gothenburg, Sweden, In vivo biomechanical stability of osseointegrating mesoporous TiO₂ implants, Acta Biomaterialia 8 (2012) 4438–4446

When the RBM surface processing in the left image is compared with the SLA (HSA) surface processing in the right image of Fig. 1, it can be seen that the SLA surface processed titanium on the right is in the state with formation of TiO₂ film on the surface. However, even the implant that has undergone such surface processing will experience occurrence of biological aging phenomenon (Biologic Aging) that hinders synostosis of the implant and the bones due to the adhesion of organic substances in the air such as hydrocarbon in about a month time. Through research on such phenomenon, Professor Ogawa of UCLA, USA has been proving that it is possible to solve the biological aging phenomenon on the implant surface through mercury UV ray Activation since several years ago. It was demonstrated that organic substances such as hydrocarbon is removed from the UV Activated implant surface, thereby resulting in the improvement of bio-affinity through exposure of the TiO₂ film on the implant surface.

2. Principle of photo-catalysis of UV implant

First, principle of photo-catalysis that removes organic substances such as hydrocarbon from the implant surface and converts the property of implant surface from hydrophobic to hydrophilic through UV Activation will be examined.



Fig.2 Radical Reaction that manifests when titanium surface is UV Activated(Source: DIO R&D Institute)

When the implant surface is UV Activated, ozone occurs. However, ozone is immediately disintegrated and disappears at the UV wavelength of less than 310nm and there is no ozone related hazard. When TiO₂ film on the SLA processed implant surface is UV Activated, electron (e-) and proton (h+) pair is released to combine with oxygen (O₂) and water (H₂O) in the air, respectively, to generate 2 types of activated oxygen made up of superoxide anion (O₂-) and hydroxyl radical (·OH). Since these activated oxygen has strong oxidizing power, it binds with C atom of organic substances such as hydrocarbon adhered to the implant surface before evaporating as CO₂, thereby resulting in clean implant surface. In this process, the electrical property of the implant surface converts from negative to positive charge with the implant surface becoming hydrophilic and immediately absorbing moisture that comes in contact.

3. Changes in the properties of the implant surface after UV Activation

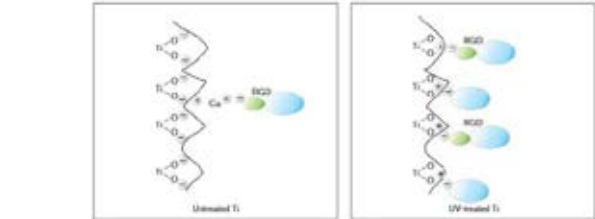


Fig.3 (Left) Mutual static electricity action between the ion and protein (green) and cell (blue) displayed on TiO₂ film without UV Activation. Ordinary TiO₂ film surface has negative charge. Since protein and cell also has negative charge, protein and cell can bind with the TiO₂ film surface only if there is presence of di valent cation such as Ca²⁺. (Right) Direct mutual static electricity action with cell (blue) on the UV Activated TiO₂ film. Since the UV Activated TiO₂ film surface has positive charge, it can bind directly with protein or cell with negative charge.(Ultraviolet Photo functionalization of Titanium Implants/ Takahio Ogawa, 2014)

When the implant surface is UV Activated, the implant surface becomes hydrophilic and will be able to absorb blood more quickly. In addition, the electrical property of the surface converts from 'negative' to 'positive' to draw in nutrients such as protein or minerals, etc. that forms bones with 'negative' charge towards the implant surface. Such phenomenon enables quick and stable synostosis to increase the implant success rate even in difficult cases with poor bone conditions or tooth extraction case, etc.




Fig.4 Reaction observed when iodine is dropped onto the implant surface prior to and after UV Activation (Source: DIO R&D Institute)

In the left image of Fig. 4, iodine was dropped onto the implant surface prior to UV Activation while iodine was dropped after UV Activation in the right image. While iodine remains on the implant surface in water drop shape in the left image, it can be seen that iodine is absorbed into the surface as soon as it is dropped in the right image.

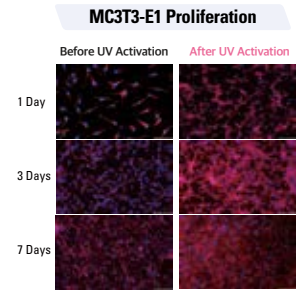


Fig.5 Reaction when the implant is immersed in real blood prior to and after the UV Activation (Source: DIO R&D Institute)

As it can be seen in the Fig. 5 on the experiment of immersing 2 implants, one with UV Activation and the other without UV Activation, into blood collected from a male in 30' s, while the implant without UV Activation repels the blood in the surrounding due to the hydrophobicity of the implant surface, UV Activated implant surface pulls in the blood in the surrounding due to its hydrophilicity.

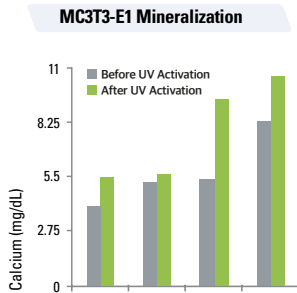
In Vitro Test-Cell proliferation experiment prior to and after UV Activation (College of Dentistry of Kyunghee University)

Cell proliferation experiment was executed by utilizing MC3T3-E1 cell line (mouse osteoblast cells) for the control group with SLA surface processed titanium disk with diameter of 10mm and the experimental group with SLA surface processed titanium disk with diameter of 10mm, which has been UV Activated.



Rapid increase in cell growth rate after 3 days on the UV Activated disk

Fig. 6 MC3T3-E1 Proliferation prior to and after UV Activation



UV displayed rapid increase in the ability to generate bones within 2-3 weeks

Fig.7 MC3T3-E1 Mineralization prior to and after UV Activation

As it can be seen in the Fig. 6 above, there was rapid increase in cell proliferation on the UV Activated Titanium Disk from the 3rd day after the commencement of the experiment in comparison to the control group without UV Activation. Based on the result of increase in the proliferation of osteoblast cells on the UV Activated Titanium Disk in comparison to Disk without UV Activation, it can be discerned that UV Activation has marked effect on osteoblast cells. Based on the results of experiment on osseo-mineralization by using SLA surface processed titanium disk with the same cell line, it can be confirmed that while the SLA surface processed titanium disk displayed increase in osseo-mineralization rate after 3 weeks, UV Activated titanium disk displayed rapid increase in the osseo-mineralization rate 2 weeks after the commencement of the experiment.

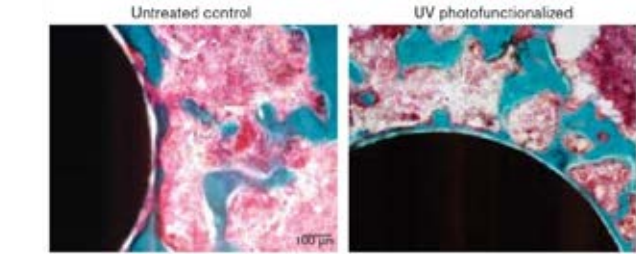


Fig.8 Evidence of increased peri-implant bone generation promoted by UV functionalization. These histologic images show peri-implant tissue at 2 weeks postimplantation in a rat femur model with and without UV treatment (Goldner trichrome)

As illustrated in the Fig. 8 above, while the UV Activated implant displays distinct difference in the osteogenesis process, areas around the implant without UV Activated have partial and localized osteogenesis. On the other hand, it can be confirmed that osteogenesis was induced extensively in the areas around the UV Activated implant without the intervention of soft tissues. In the biodynamic test with experimental mouse model, UV Activated implant had BIC of 72% 2 weeks after the loading of the implant, which is 2.5 times higher than the control group without UV

- Graduate of The Busan National University Dental College, Korea
- DIO Key Doctor Board Member
- Member of International Congress of Oral Implantologists
- Present) NYU-Linhart continuing dental education program lecturer
- Present) Chairman of Newton Dental Hospital



Activation. BIC increased to 98.2% 4 weeks later, which is approximately 2 times higher than that of the control group at 53%. Through these results, it can be discerned that UV photo activation not only accelerates the synostosis process but also increases the quantity of osteogenesis. (Ultraviolet Photo functionalization of Titanium Implants/ Takahio Ogawa, 2014)

4. Success rate, healing time and stability of UV Activated implant

In 2014, Professors Akiyoshi Eunato, Masahiro Yamada and Takahiro Ogawa, etc. analyzed 95 patients who underwent 222 cases ordinary implant procedure and 70 patients who underwent 168 cases of UV Activated implant procedure over a period of 2.5 years. More than 90% of the implant procedures in both groups were difficult case that required stepwise or simultaneous surgeries.




Fig.9 Healing time before functional loading of untreated and photo functionalized implants. Shaded and white boxes account for 50% and 80% percentile, while the mean values are denoted above each box. Ut:Untreated implants, PF:photo functionalized implants, *P < .05

As the results of the research, loading of photo activated implant displayed high success rate of 97.6 % with 3.2 months needed for healing up to the time of loading, which is a substantial reduction in comparison to 6.5 months for the control group, as illustrated in the Fig. 9 above.

Table1 ISQ Change and Increase for Photofunctionalized Implants				
Primary stability range	Implants	ISQ		
		At placement (ISQ)	At loading	Increase/m
ISQ< 40	3	37.7 ± 2.3	63.0 ± 7.5**	4.6 ± 0.4
ISQ 40-49	8	47.6 ± 1.8	73.8 ± 8.6***	8.7 ± 4.1
ISQ 50-59	13	56.1 ± 2.7	66.8 ± 8.7***	2.6 ± 2.4
ISQ 60-69	18	66.5 ± 2.6	70.5 ± 12.4 ^{NS}	NA
ISQ 60-64	4	62.8 ± 1.5	74.0 ± 7.2*	2.0 ± 1.5
ISQ 65-69	14	67.6 ± 1.5	69.5 ± 13.5 ^{NS}	NA
ISQ 70-79	33	76.1 ± 1.9	72.4 ± 11.5 ^{NS}	NA
ISQ ≥ 80	24	82.7 ± 1.9	80.4 ± 6.1 ^{NS}	NA

ISQ 60-69 was subdivided into ISQ 60-64 and 65-69 groups to precisely determine threshold of significant change in ISQ at loading.
Statistically significant differences between time points: *P < .05; **P < .01; ***P < .001; NS: not significant.
ISQ: initial ISQ at implant placement; NA: not applicable.

The increase in the ISQ value of photo activated implant was in the range of 2.0~8.7 every month, which is higher than the increase in the ISQ value of control group in the range of -1.8~2.8 stated in literatures.

Table 2 Implant Data							
	Overall implant length			Implant diameter		Complex cases	
	Mean (mm)	≤ 10 mm (%)	≥ 13 mm (%)	Mean (mm)	≥ 5 mm (%)	Implant length (mm)	Implant diameter (mm)
Untreated implants (n = 222)	12.04 ± 1.69	56 (25.2)	109 (49.1)	4.71 ± 0.75	123 (55.4)	12.20 ± 1.65	4.64 ± 0.73
Photofunctionalized implants (n = 168)	11.76 ± 1.60 ^{NS}	63 (37.5)	72 (42.9)	4.51 ± 0.71**	66 (39.3)	11.71 ± 1.30*	4.50 ± 0.76 ^{NS}

Statistically significant differences between untreated and photofunctionalized groups: *P < .05, **P < .01, NS: not significant.

The photo activated group used implant with length of less than 10mm more extensively and the diameter of the implant used was smaller in comparison to that of the control group on the average. In conclusion, in spite of the use of the implant with shorter length and smaller diameter more often, it was possible to use quicker loading protocol without having to decrease the success rate through photo activation. This is associated with the speed of increase in the stability of the photo activated implant. This result suggests that photo activation can provide new and realistic method for further advancement of implant procedure. (Success Rate, Healing Time, and Implant Stability of Photo functionalized Dental Implants / Akiyoshi Eunato, Masahiro Yamada, Takahiro Ogawa, 2014)

Efficacy and Clinical Utilization of UV Activated Implant

I . Efficacy of UV Activated Implant / II . Clinical Utilization of UV Activated Implant

II. Clinical Utilization of UV Activated Implant

5. Clinical Case

With the increase in the demands and more challenging implant surgeries, there has been increasing interest among dental clinics on immediate and early stage loading of the implant. Whether such demand can be met when loading without incision through Digital Guided Surgery will be examined through clinical cases on the basis of theoretical and experimental results of UV Activated implant.

Case 1)

72-year old male patient who is takes heart medications visited the hospital due to inconveniences in the existing 6 UNIT Bridge from no.13 to 23. Deep cervical caries were observed in the 13 and 23 teeth and the root condition of 11 tooth was poor. As such, 22, 13 and 23 teeth were extracted, and implant was loaded at the positions 11, 13, 21 and 23 before establishing treatment plant with implant Bridge from 11 to 13, and 21 to 23.

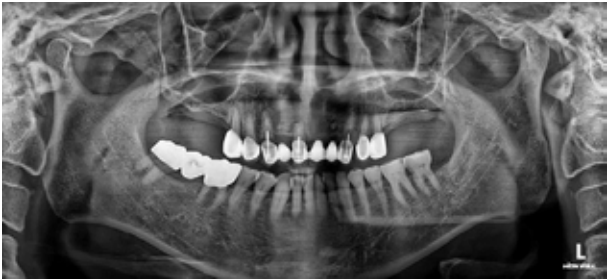

Fig.10 Panoramic photo at the initial examination

Oral scan and CBCT data were obtained for Digital Guided Surgery 3 months after tooth extraction and surgical guide was designed after having positioned implant at appropriate position with the software with considerations for the shape and location of the final tooth.



Fig.11 Planning Software (Implant Studio)

Fig.12 Surgical Guide Design (Implant Studio)

Implant information			
Implant location (UNN)	13	11	21
Manufacturer	DIO	DIO	DIO
Type	UF(III)3810	UF(II)3810	UF(III)3810
Order No.	UF(III)3810	UF(III)3810	UF(III)3810
Length, mm	10	10	10
Diameter (Ø), mm	3.8	3.8	3.8
Color	Blue	Blue	Blue

Implant information	
Implant location (UNN)	23
Manufacturer	DIO
Type	UF(III)3810
Order No.	UF(III)3810
Length, mm	10
Diameter (Ø), mm	3.8
Color	Blue

Fig.13 Implant analysis data

Since the recently updated software indicates the bone density for each distal, proximal, buccal and lingual aspect by computing the bone density around the implant, as illustrated in the Fig. 13, it is not much easier to secure appropriate initial fixation prior to the surgery through analysis prior to the procedure.



Fig.14 DIO UV Activator 1



Fig.15 DIO UV implant and UV Activator 2

Procedure was executed in Flapless Digital Guided Surgery format after printing the designed guide with a 3D printer. 4 DIO implants were UV-treated with UV Activator 2 for 20 seconds before placement. Since the existing UV Activator 1 (Fig. 14) neededs 15 minutes to Activate UV light This resulted in the problem of having to wait for 15 minutes for the implant to be UV activated in the middle of surgery when placing implants with different dimension from the original plan during the surgery Since the Activation time markedly shortened to 20 seconds for the UV Activator 2 (Fig.15) it was possible to easily cope with variables that manifest in the surgical process, and it was highly satisfactory from the perspective of the surgeon.

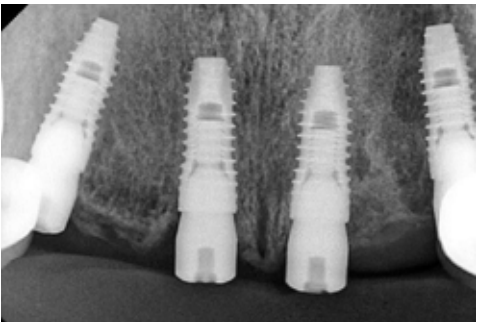


Fig.16 Radiograph image of root apex after surgery

Dental formula NO.	Implant Size	Bone Density	ISQ				
			DØ	1 Week	2 Week	3 Week	4 Week
#13	DIO UV Ø 3.8X10mm	D2~D3	65	65	75	75	76
#11	DIO UV Ø 3.8X10mm	D3	65	66	80	80	81
#21	DIO UV Ø 3.8X10mm	D3	68	68	73	73	74
#23	DIO UV Ø 3.8X10mm	D2~D3	80	80	82	82	83

Table 1, ISQ measurement values immediately after the surgery and at 1 week interval thereafter.

Fig. 16 shows the radiograph image of root apex immediately after embedding of implant and the ISQ values measures immediately after the surgery and at 1 week intervals thereafter are illustrated in the Table 1. All 4 implants displayed ISQ values of more than 70 in the 2nd week and production of prosthesis was executed on the 4th week. ZIRCONIA prosthesis was produced in modeless method by using oral scanner for the left side while PFM prosthesis was produced by using impression for the right side since it was insurance covered implant.

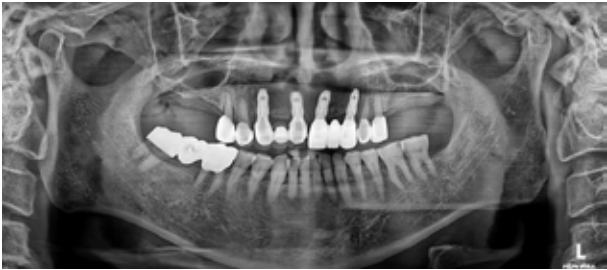

Fig.17 Panoramic photo after the final prosthesis

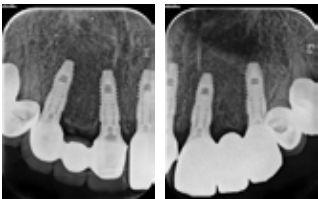


Fig.18 Radiograph image of root apex after the installation of final prosthesis

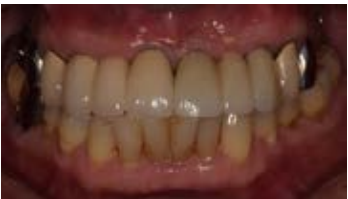

Fig.19 Photograph of teeth after the installation of final prosthesis

Changes in the ISQ values of the implants embedded in the maxillary anterior teeth area shows increase in the values on the 2nd week, thereby illustrating that synostosis of the implant and alveolar bone can be achieved within short period of time through Digital Guided Surgery and UV implant.

Case 2)

51-year old male patient without any specific past history of diseases visited the hospital to restore maxillary molar teeth on the right side. Since there was approximately 9mm of residual bone, treatment plan was made to place 8.5mm UV implants at the 17 and the 16 teeth locations without bone graft.

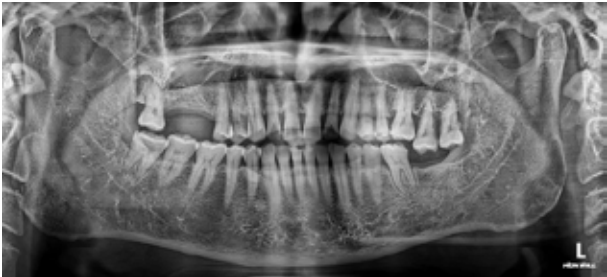

Fig.20 Panoramic photo at the initial examination

After acquiring oral scan and CBCT data the position of the implant was designated with the software, and the surgical guide was designed.

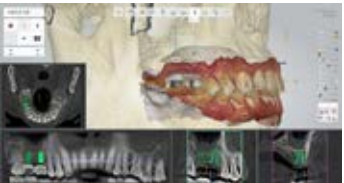


Fig.21 Planning Software (Implant Studio)

Implant information	
Implant location (UNN)	17
Manufacturer	DIO
Type	UF(II)5008
Order No.	UF(II)5008
Length, mm	8.5
Diameter (Ø), mm	5
Color	Green
Sleeve information	
Name	DIO GS 53
Type	Completely guided
Order No.	GS 53
Offset, mm	9
Color	Blue
Drill information	
Minimum drill length	17.5

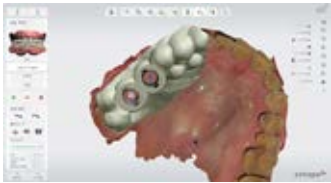

Fig.22 Surgical Guide Design (Implant Studio)

Implant information	
Implant location (UNN)	16
Manufacturer	DIO
Type	UF(II)5008
Order No.	UF(II)5008
Length, mm	8.5
Diameter (Ø), mm	5
Color	Green
Sleeve information	
Name	DIO GS 53
Type	Completely guided
Order No.	GS 53
Offset, mm	9
Color	Blue
Drill information	
Minimum drill length	17.5

Fig.23 Implant analysis data

Procedure was executed in Flapless Digital Guided Surgery format after printing the designed guide with 3D printer. 2 DIO UV implants were Activated with UV Activator 2 for 20 seconds prior to the surgery and placed thereafter.

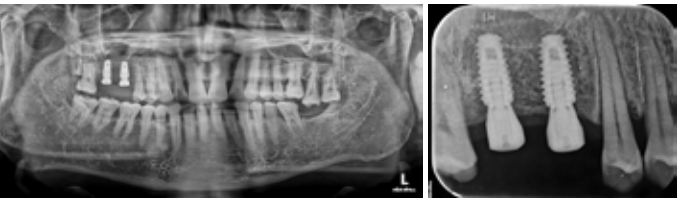


Fig.24 Panoramic photo and radiograph image of root apex after the surgery

ISQ values measures immediately after the surgery and at 1 week interval thereafter were as follows.

Dental formula NO.	Implant Size	Bone Density	ISQ			
			DØ	1 Week	2 Week	3 Week
#17	DIO UV Ø 5.0X8.5mm	D3	72	74	81	82
#16	DIO UV Ø 5.0X8.5mm	D3	65	69	75	79

Table 2, ISQ measurement values immediately after the surgery and at 1 week interval thereafter.

All the ISQ values were higher than 70 in the 2nd week and ZIRCONIA prosthesis was produced on the 4th week using an oral scanner.

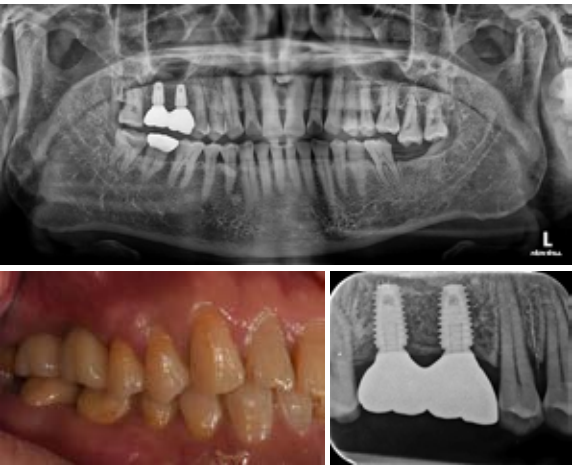

Fig.25 Panoramic photo, oral cavity photo and radiograph image of root apex after the installation of final prosthesis

Regarding the changes in the ISQ values of implants placed in the maxillary molar area, it was possible to observe the increase in the values on the 2nd week. It was also possible to obtain synostosis of the implant and alveolar bone within short period of time through UV Activation in spite having to use an implant with even shorter length (8.5mm).

Effects of UV implant on synostosis in cellular experiment, animal experiment and clinical settings were examined above along with the theoretical considerations on the UV implant. As such, it was confirmed that UV Activation on the implant surface can clean the implant surface by removing organic substances such as hydrocarbon accumulated as the result of biological aging phenomenon UV Activation on the implant surface can also induce quicker synostosis and high BIC by not only transforming the nature of implant surface from hydrophobic to hydrophilic but also promoting adherence of protein and cells by changing the electric charge of the surface from negative to positive. Through such process, it is deemed that UV implants can be used assertively not only in difficult cases including cases with low bone density or immediate placement after tooth extraction but also in the cases of immediate or early stage loading.

Newton Dental Hospital Dr. Hyunlak Son

- Graduate of The Busan National University Dental College, Korea
- DIO Key Doctor Board Member
- Member of International Congress of Oral Implantologists
- Present) NYU-Linhart continuing dental education program lecturer
- Present) Chairman of Newton Dental Hospital



Efficacy and Clinical Utilization of UV Activated Implant

III. Theoretical base for ISQ measurement for determination of the early stage implant load and the effects of UV Activation on the time of loading / IV. Overcoming difficult cases by using UV Activated implant

Yedam Dental Hospital **Dr. Kang, Jae Seok**



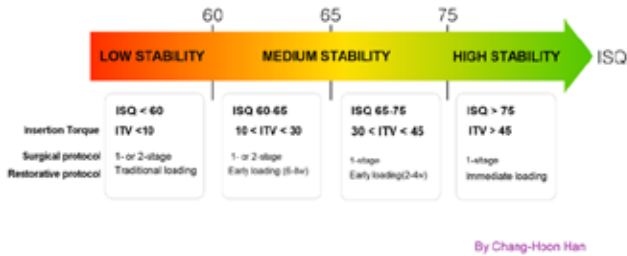
III . Theoretical base for ISQ measurement for determination of the early stage implant load and the effects of UV Activation on the time of loading

- Trained and received Ph.D. in dental science at the Prosthetics Department of the Dental College of Chosun University
- Visiting scholar to Periodontal–Implant Department of Pennsylvania Dental College
- Linhart continuing dental education program lecturer at the New York Dental College
- Current) Adjunct professor at the Prosthetics Department of the Dental College of Chosun University

Until now, opinion that activation of UV onto the implant surface in appropriate method will be beneficial for early stage osteogenesis has been presented and was verified through the thesis by Professor T. Ogawa of UCLA in 2014 and results of other animal experiments, Benefits of UV Activated implant surface including increased protein absorption, increased contact of osteoblastic cells, increased retention of cells, promoted proliferation of cells, promotion of osteoblast differentiation, increase in the speed of synostosis, marked increase in bone–implant binding, prevention of the loss of Stability Dip that occurs in the 3rd ~ 4th week after placement, and removal of surface hydrocarbon, etc. were reported in laboratory researches along with the disclosure that these phenomenon do not occur independently but through close interaction with each other. Such theoretical advantages of UV surface treatment are being verified through clinical experiments. According to Ueno et al., if the embedded implant is healed without the support of cortical bone, strength of synostosis was reduced by 60% in the ordinary implant while the UV treated implant displayed the extent of synostosis that is similar to the ordinary implant healed with the support of cortical bone. At the same time, there was presence of aspect of contact osteogenesis in which the osteogenesis that began at the implant surface continues onto the surrounding bones (Fig. 1–1).

Measurement of Implant Stability Quotient (ISQ) value based on Resonance Frequency Analysis (RFA) among various methods of measuring the implant stability has been reported as a non–destructive method with high reliability and efficacy. Although electronic device (Osstell®; Integration Diagnostics AB, Göteborg, Sweden) to which L–shaped transducer is connected was used for RFA in the initial stage, Osstell Mentor® (Integration Diagnostics AB) or Osstell ISQ® (Integration Diagnostics AB) with contact–free probe using magnetic receptor, SmartPeg® (Integration Diagnostics AB), is used at the moment. Although there are differing opinion in various theses on the correlation between the measured ISQ value and synostosis, follow–up observation by measuring the ISQ values at prescribed interval after the implant placement will provide highly useful ground for estimation and determination of whether synostosis is being carried out successfully for each implant. Currently, Osstell IDX, which is capable of accumulating data by storing dental formula, supports color screen and has the function for linkage with electronic chart in comparison to Osstell mentor, is commercially available (Fig. 1–3).

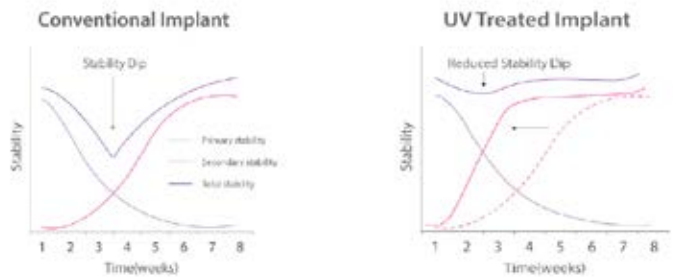
Loading Protocols of Single-missing



(Fig. 1–4) Appropriate time of loading by using ISQ value (By Han, Chang Hoon)

2. Effect of photoactivation (UV Activation) on the time of loading

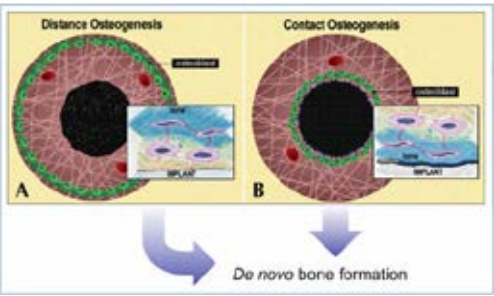
In 2013, Professors A. Funato and T. Ogawa confirmed in 2013 that UV surface treatment enables shortening of the implant treatment time through quicker loading without decreasing the success rate of implant. This has also been proven in Korea on the basis of extensive clinical results (Fig. 1–5).



(Fig.1–5)UV treated titanium surface induce faster bone healing around the implant, Fast increase of secondary stability reduce stability dip during 2 to 4weeks after implant placement.

Makato Hirota (2016) made comparison of the speed of improvement in the stability of photoactivated dental implant for both ordinary and difficult cases through the use of ISQ values and reported that photoactivation in particular accelerates the speed of osseointegration onto implants in cases of bones with poor osseous tissues and other difficult cases, improves stability level in comparison to ordinary implant, which acted as decisive factor from the perspective of implant stability in comparison to other host related factors that had already been tested.

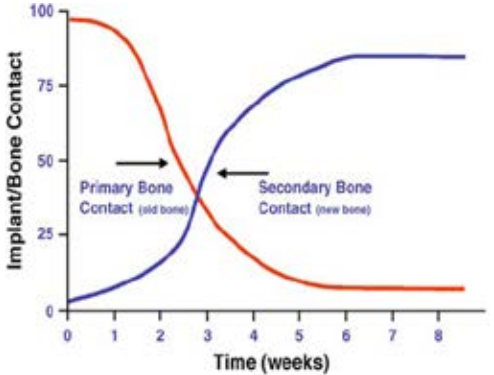
Akiyoshi Funato (2013) reported that all implants were maintained functionally and in good health after 1 year in spite of early stage loading for all implants (2.1 ~ 4.5 months) including immediate placement after tooth extraction, vertical bone graft, maxillary sinus lifting case and placement in failed implant area. ISQ increased from 48~75 at the time of implant placement to 68~81 at the time of loading. In particular, ISQ of the implant with low early stage stability (early stage ISQ <70) increased markedly. It was found that the use of photoactivated dental implant in clinically difficult case induces synostosis in shorter period of time than that presented in the ordinary procedure and existing literatures. In addition, the stability of the implant and increase in the speed of synostosis were substantially higher in the case of photoactivated implant in comparison to the similar cases reported in literatures. While the quantity of bones around all implants increased in the cases with low marginal bone level (MBL) in comparison to the upper part of the implant at the time of final prosthesis during the 1 year of follow up period, implant for which sufficient bone around the implant was secured at the time of the final prosthesis maintained its level (Table 1–1).



(Fig. 1–1) Drawings from Davies JE (1998 and 2003) that show the initiation of distance osteogenesis (A) and contact osteogenesis (B)

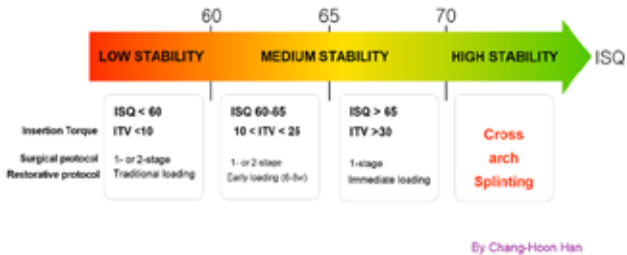
1. Theoretical grounds for ISQ measurement for determination of early stage load

Implant is fixated by mechanical retention force due to the friction with the existing bones after placement. Such mechanical fixation force decreases as the existing bones are absorbed and it takes relatively long time for remodeling of bone or in order for new bone to be generated and matured on the implant surface to support the implant (secondary implant stability). Therefore, there is a temporary period of degraded stability after implant placement due to such temporal difference (implant stability dip). It is recommended that application of load to the implant be avoided as much as possible during this period of stability dip (critical period) and this has become the reason for clinical surgeons in hesitating early stage or immediate loading after the implant placement (Fig. 1–2).



(Fig. 1–2) Red line– Initial stability (Perio test, ISQ values), Blue line– 2nd stability(Contact osteogenesis and distance osteogenesis). From surgery to 2 or 3 week is most critical period in osseointegration

Loading Protocols of Completely edentulous



Loading Protocols of Partially dentated

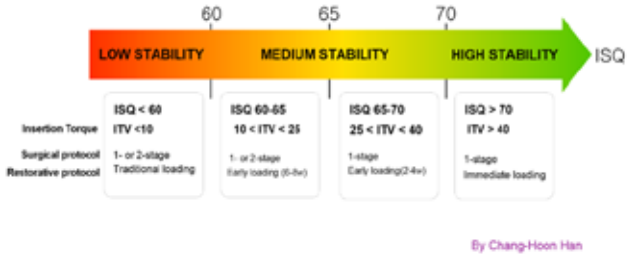


Table 1 Case Description and Clinical Outcome Parameters							
Patient	Surgical procedure	ISQ			MBL		
		Time before loading (mo)	At implant placement	At loading	At definitive restoration	After 1 y	Change
Patient 1	Immediate replacement of failing implant	2.1			-0.8 (M)	-0.2	+0.6
					-1.4 (D)	-0.7	+0.7
Patient 2	Simultaneous sinus elevation	3.8	48	76	7.36	0.4 (M)	0.0
			49	80	8.16	1.0 (D)	0.0
					1.0 (M)	1.0	0.0
					-0.6 (D)	-0.4	+0.2
Patient 3	Fresh extraction socket	2.1	67	72	2.38	-0.3 (M)	0.5
					-1.1 (D)	-0.6	+0.5
Patient 4	Staged approach: Vertical GBR and sinus elevation	4.5	67	80	2.89	-0.8 (M)	-0.2
					-0.7 (D)	0.0	+0.7
			75	81	1.33	-0.2 (M)	0.5
					-0.6 (D)	0.2	+0.8
			73	68	-1.11	-0.7 (M)	0.5
					-0.2 (D)	0.2	+1.2
Mean		3.6	63.2	76.2	3.5	-0.35	0.16
SD		1.0	11.8	5.2	3.5	0.71	0.53

(Table 1–1)

As illustrated above, it can be seen that UV Activated implant enables early stage loading with display of quick osteosynthesis in areas such as the area of bone graft, area of maxillary sinus lifting with inadequate residual bone and area of tooth extraction, and determination of such timing can obtain good results by utilizing ISQ values properly. In the next issue, I will introduce the effects of UV Activated implant in actual clinically difficult cases on the basis of such possibilities and cases that verified such effects by using ISQ values (continued in the next issue).

(REFERENCE)

Ueno T, Yamada M, Suzuki T., Enhancement of bone–titanium integration profile with UVphotofunctionalized titanium in a gap healing model, Biomaterials, 2010; 31:1546–1557.

Han, Chang–Hun., Immediate Loading of Tapered Implants Placed in Postextr action Sockets and Healed Sites Journal of Craniofacial Surgery: July 2016–Vol ume 27–Issue 5–p 1220–1227

M, Hirota., Implant Stability Development of Photofunctionalized Implants Plac ed in Regular and Complex Cases:A Case–Control Study Quintessence Publishi ng co, Inc, volume 31, Number 3, 2016

A,i Funato., Photofunctionalized Dental Implants:A Case Series in Compromis ed Bone research

The International Journal of Oral & Maxillofacial Implants/Quintessence Publis hing co, Inc, 2013

Hyon–Woo Seol., Resonance Frequency Analysis and Early Loading of Implants with Sealed UV Treatment System: Case Reports, Implantology 2017

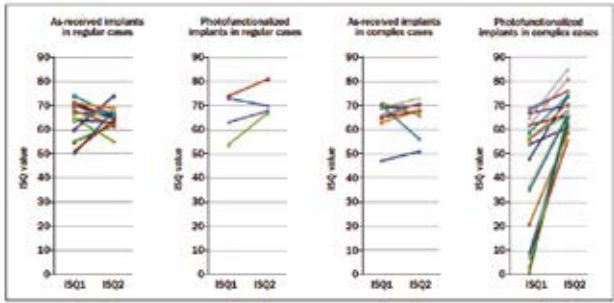
Cochran D.,The evidence for immediate loading of implants, J Evid Base Dent Pract 2006;6:155<63

Efficacy and Clinical Utilization of UV Activated Implant

III. Theoretical base for ISQ measurement for determination of the early stage implant load and the effects of UV Activation on the time of loading / IV. Overcoming difficult cases by using UV Activated implant

IV. Overcoming difficult cases by using UV Activated implant

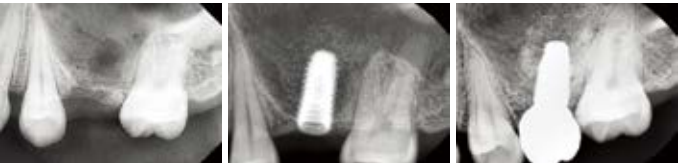Team of professors Makoto Hirota and Tomomichi Ozawa of Yokohama University, Japan compared the implant stability through the measurement of ISQ values during the process of osteosynthesis by placing both the UV Activated and non-Activated implants into the maxillary sinus lifting area accompanied by bone graft and area of bone graft requiring artificial placing, which are classified as clinically difficult cases, in 2016. As the results, they reported that photoactivation of implant surface accelerated the speed of placing particularly in bones with poor osseous tissues and other difficult cases of implant and improved the stabilization level in comparison to the ordinary implant with UV treatment acting as more decisive factor than other already tested host related factors from the perspective of implant stability (Table 1-1).On the basis of the aforementioned results, I also obtained excellent results by placing UV Activated implant into maxillary sinus area with insufficient residual bones, area needing extensive alveolar bone graft, and areas needing re-placement due to tooth extraction and failure in implant osseointegration for various reasons, along with digital guide (DIONavi.). As such, I would like to introduce them in this paper.



(Table 1-1) Implant stability quotient at placement (ISQ1) and stage-two surgery (ISQ2) of as received (untreated) and photofunctionalized implants. Implants were divided into two groups of regular and complex cases. The complex cases included the implant placement with either simultaneous guided bone regeneration (GBR) or sinus elevation, or placement in a fresh extraction socket

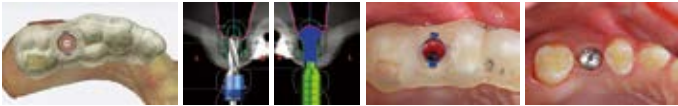
1. Effects in the case of having executed maxillary sinus lifting and UV Activated implant simultaneously with residual bone of less than 5mm

[Case 1] In this case of 22-year old female patient with a lot of fear towards dental treatment, 3mm of residual bone in the maxillary sinus was confirmed under radiation examination. As such decision was made to perform implant placement along with maxillary sinus lifting. Consultation was provided for procedure without incision by using digital guide for the patient. Findings prior to and after the surgery, and after finishing radiation are as follows (Fig. 1-1).



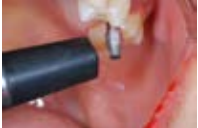(Fig. 1-1) Radiation examination images from the early stage of surgery to the time of completion of prosthesis (3.5 months)

At the time of surgery, digital guide (DIONavi.) manufactured in advance and maxillary sinus surgery kit for exclusive application for guide was used. After having lifted the maxillary sinus membrane by using maxillary sinus drill and water pressure, UV Fixture (DIO UFII) with diameter of 5.0mm and length of 11.5mm was activated for 20 seconds with DIO UV Activator II before placing it along with bone graft (heterogeneous bone) simultaneously. ISQ value measured after the was 68. Healing abutment was connected at the top portion of embedded implant (Fig. 1-2).



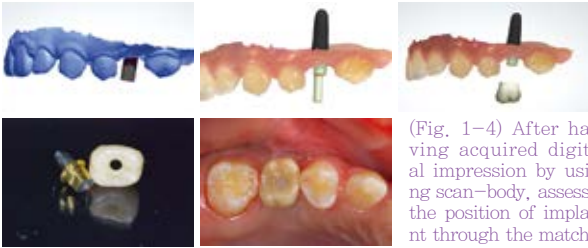(Fig. 1-2) Flapless surgery using digital guide, water pressure and guide

The patient was instructed to visit the hospital at prescribed interval for measurement of ISQ (Osstell mentor) to determine the time of loading (Fig. 1-3, Table 1-2).



(Fig. 1-3) Measure ISQ value

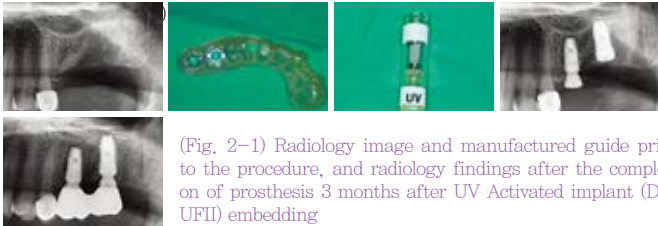
Generally, in the event of placing implant along with maxillary sinus lifting when the residual bone is less than 5mm, it takes approximately 6 months until loading is possible through integration of the bone graft material and implant. However, in this case, loading was performed 3 months after placement since ISQ value of more than 75 was obtained after 3 months. The patient is using the implant without any problem at the present, 10 months after the implant placement. As in the report made by A. Funato (2013) and M. Hirota (2016) mentioned in the previous issue, it can be seen that UV Activated implant imparts substantial influence on the early stage osseointegration even in the difficult maxillary sinus cases. Digital impression acquisition for prosthesis was performed through scanning by connecting the scan-body to the implant and using intra oral scanner, Trios3 (3Shape). When merging process is executed by using Dental system (3Shape) program, implant position is planned digitally. Final prosthesis was designed after having selected the ready-made stock abutment (DIO) available in the program library and was manufactured with zirconia (Fig. 1-4).



(Fig. 1-4) After having acquired digital impression by using scan-body, assess the position of implant through the matching process in the Dental program (3 Shape) before selecting the stock abutment (DIO) from the library to design the final prosthesis. All the processes were carried out digitally without model.

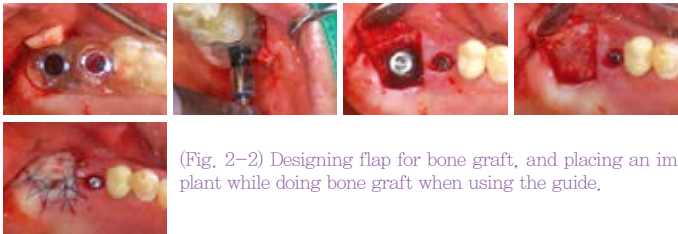
2. Effect of UV Activated implant placement in the area of tooth extraction and extensive loss of alveolar bone

[Case 2] This 64-year old male patient visited our hospital with the history of tooth extraction due to severe tooth mobility about a month ago. He requested for navigation implant (expression used by the patient) at the tooth extraction site(#27) and at the location where tooth was already lost(#26).As the results of radiology examination, the #26 had healthy alveolar bone while the #27 displayed severe bone loss due to tooth extraction and after effect of inflammation. This location required implant placement and extensive alveolar bone graft at the same time.Generally, many people think that digital guide procedure is not possible in the cases accompanying severe bone graft. However, even in such cases, digital guide procedure in accordance with the request of the patient is possible. The advantages of using guide at this time include ability to execute entire prosthesis processes in digital format while placing the implant in the desired location. In the case of this patient, data for guide was obtained by using Trios3 (3Shape) oral scanner and CBCT to design the guide with Implant studio (3Shape) program and manufactured with in-house 3D printing. At the time of the surgery, implant exclusive for UV was activated for 20 seconds with Activator II (DIO) prior to placement. It took a total of 3.5 months from placing to finishing of prosthesis and radiological findings are as UV



(Fig. 2-1) Radiology image and manufactured guide prior to the procedure, and radiology findings after the completion of prosthesis 3 months after UV Activated implant (DIO UFII) embedding

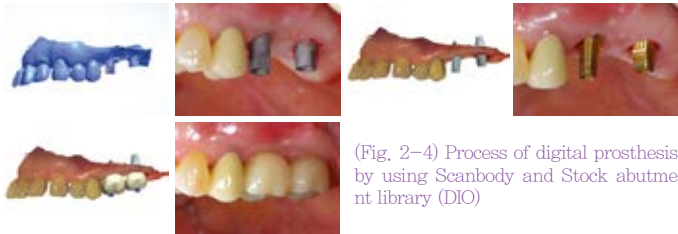For the location that does not need bone graft, incision was made in a flapless method by using the guide, and for the location that needs bone graft, incision was made by designing the flap to move to the buccal side to ensure there is no problem when using the guide. Then, UV Activated implant (DIO UFII) was placed along with heterogeneous bone before covering with PRF membrane (Fig. 2-2).



Section #27 which was bone grafted, was exposed to enable ISQ value measuring by using the digital guide and punch which was used during surgery after 1 month of when soft tissue healing is done. ISQ values were continuously measured at the interval of 1 month thereafter. It was decided to manufacture prosthesis since ISQ value (of more than 75) that enables loading was obtained at the 3rd month in the bone grafted location (Fig. 2-3, Table 2-1).

	Surgery	1month	2months	3months	4months
#26	67	75	81	83	85
#27	21	52	64	75	81

After acquiring digital impression by using Trios3 (3Shape) oral scanner after attaching the scan-body to the implant for the manufacturing of the final prosthesis, the position of the implant was confirmed through merging process under the Dental system (3Shape) program. Then, the final prosthesis was designed by selecting the ready-made stock abutment (DIO) from the library. Final prosthesis was manufactured by using zirconia and all the processes were executed through digital process without the need for a plaster model(Fig. 2-4).



(Fig. 2-4) Process of digital prosthesis by using Scanbody and Stock abutment library (DIO)

Generally, it is necessary to wait a minimum of 4~5 months for osseointegration after placing an implant along with bone graft in the case of extensive bone loss in the maxillary molar area. However, it can be seen that there was a faster osseointegration when placing a UV Activated implant.

3. In the event of re-placing UV Activated implant in the location where implant placement failed the first time.

Yedam Dental Hospital Dr. Kang, Jae Seok

- Trained and received Ph.D. in dental science at the Prosthetics Department of the Dental College of Chosun University
- Visiting scholar to Periodontal-Implant Department of Pennsylvania Dental College
- Linhart continuing dental education program lecturer at the New York Dental College
- Current Adjunct professor at the Prosthetics Department of the Dental College of Chosun University



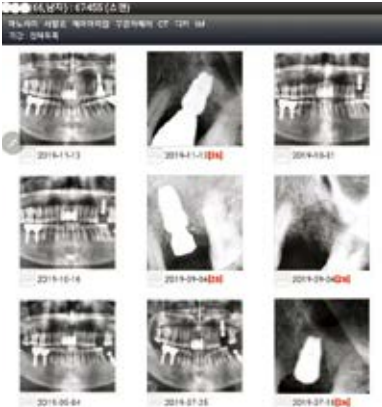Akiyoshi Funato(2013) reported that ISQ value increased markedly in early stage even in the cases of immediate placement after tooth extraction, vertical bone graft, maxillary sinus lifting and low early stage stability of extensive implant placed in the previously failed location (early stage ISQ <70). I was also able to observe rapid increase in the ISQ values at an amazing pace in the case of having re-placed UV Activated implant in the locations of previous implant failure for various reasons in comparison to that of the ordinary implant. I was able to restore the deteriorated relationship with the patient by completing the prosthesis earlier than usual.

[Case 3] This 66-year old male patient had difficulty in controlling his smoking habit. Although the implant was placed into the corresponding position, the soft tissue did not heal all the way. As such, healing abutment was connected, but the placed implant had to be removed due to detection of increased mobility and bone absorption around the implant under the radiology imaging. 2 months after the removal, sequestrum and inflammatory tissues were thoroughly removed for re-placing. Then, UV Activated implant (DIO UFII) accompanied by additional bone graft was placed. After having executed the 2nd surgery by using Punch for ISQ value measurement 1 month after the initial surgery, healing abutment was attached. Impression was acquired and final prosthesis was manufactured since ISQ value (77) for which loading is possible was displayed 2 months after the resurgery (Fig. 3-1).



(Fig. 3-1) Measurement of extent of fixation of re-placed implant and image of the final prosthesis

As the corresponding patient was undergoing implant treatment under the coverage of insurance policy, all the process were carried out through general impression acquisition method while the final prosthesis was manufactured with PFM. I would like to introduce all the radiology images and dates stored in the patient management program in this paper in order to avoid any possible controversies (Fig. 3-2).



(Fig. 3-2) Implant placement and removal after failure, re-placement of UV Activated implant, period and radiology images until the final prosthesis

As illustrated above, as the results of having used UV Activated implant in a wide range of difficult cases including implant placing simultaneously with maxillary sinus lifting with little residual bone, placement accompanied by tooth extraction and extensive bone graft, and re-placement due to implant failure because of various reasons, etc, by making reference to the cases reported in various literatures, I managed to verify the substantially quicker speed of healing and stability of UV Activated implant in comparison to ordinary non-activated implant. Therefore, I am introducing them here.

(REFERENCE)
1. A. Funato., Photofunctionalized Dental Implants:A Case Series in Compromised Bone Research The International Journal of Oral & Maxillofacial Implants / Quintessence Publishing co, Inc, 2013
2. M. Hirota., Implant Stability Development of Photofunctionalized Implants Placed in Regular and Complex Cases: A Case-Control Study Quintessence Publishing co, Inc, volume 31, Number 3, 2016

Overcome the Limitation in Surface Processing of Implant! UV Irradiation

I. Literature review on UV irradiated implant / II. Clinical difference between SLA surface finishing and UV irradiated implant / III. Utilization of UV irradiated implant in difficult case / IV. Utilization of UV implant in guide procedure


I. Literature review on UV irradiated implant

A wide range of researches and developments for surface processing had been carried out to increase the success range of implant including shortening of the healing time for osseointegration, fortification of resistance against inflammation around the implant and application for difficult cases (lack of insufficient initial bone contact area between the aged bone or bone and implant, etc.). In particular, interest on appropriate surface finishing of implant for elderlies with poor osseous tissues due to rapid aging of population in Korean society and covering of the cost of implant under the National Health Insurance Plan, thereby reducing the financial burden individuals have to bear.

Recently, sandblasted with large grit and acid etched (SLA) surface finishing that not only increased the mechanical surface but also optimized the biological stability of the implant surface appears to be recognized as the most generalized surface finishing.

However, even the SLA surface finishing evaluated to have most stable surface roughness for the implant and bi-friendly displayed manifestation of biologic aging that interfere with integration of bone and implant due to adhesion of organic matters such as hydrocarbon in the air as time passes after surface processing. In order to resolve this issue, UV irradiated implant has been introduced. This is a fact that has been researched in diversified formats and proven since several years ago by professor Ogawa of UCLA, USA. It has been reported that reforming change for the implant surface through UV irradiation can achieve the following: 1) implant surface changes from hydrophobic to superhydrophilic, 2) increase the BIC ratio to ideal level, 3) induce osseointegration strength of the short implants with relatively small surface area to the surface area equivalent or higher than that of the ordinary sized implant, 4) shorten the time taken for healing of implant, and 5) effects on suppression of inflammation around implant, etc. These effects are collectively referred to as the UV Photofunctionalization. As such, this study reviews the clinical application of UV irradiated implant as a means of overcoming the limitations of implant surface processing by beginning with theoretical and literatures reviews.

I. Literature review on UV irradiated implant



Biologic Aging

Unlike the Resorbable Blasting Media (RBM) that widens the mechanical implant surface area by pressurized spraying of hydroxyapatite powder, implant surface that has been SLA surface processed in order to increase the mechanical surface area through pressurized spraying of alumina (Al2O3) powder and maximize the

bio-friendliness through etching by strong acid at high temperature is equipped with stable formation of TiO₂ oxidation membrane, thereby establishing the conditions capable of accelerating osteogenesis. (Fig. 1) **Fig. 1** TiO₂ layer formed at the outer boundary of SLA surface finish _ Martin Anderson, Department of Chemical and Biological Engineering, Applied Chemistry, Chalmers University of Technology, Gothenburg, Sweden

However, according to the research results, it was confirmed that hydrocarbon that exists in the air covers approximately 60~75% of the entire surface area after about 1 month, thereby resulting in the manifestation of biologic aging that interferes with the osseointegration between the implant and bone.

UV [UV Photofunctionalization]

Implant surface becomes hydrophobic due to organic matters such as hydrocarbon and the ability to pull factors that form bones such as protein, etc. gets degraded. However, it was possible to observe that irradiation of the implant surface with UV ray exposed TiO₂ layer on the surface through removal of organic matters such as hydrocarbon,

thereby maximizing bio-friendliness.

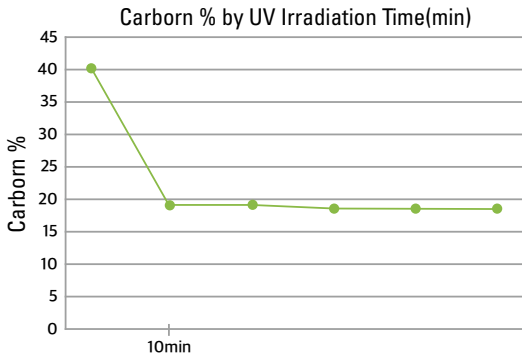


Fig. 2 Source of data: DIO R&D Institute

1) Removal of organic matters such as hydrocarbon

Hydrocarbon that covered 60~75% of the implant surface prior to UV irradiation dropped to 20% level after 10 minutes of UV irradiation with no change even if the duration of UV irradiation is increased, (Fig. 2) (Ultraviolet Photofunctionalization of Titanium Implants / Takahiro Ogawa, 2014).




Fig.3-1 Conversion from hydrophobic to hydrophilic surfaces of titanium by UV treatment. Top and side view images are shown of 10μ L of water on acid-etched and sandblasted titanium disks before and after UV treatment.

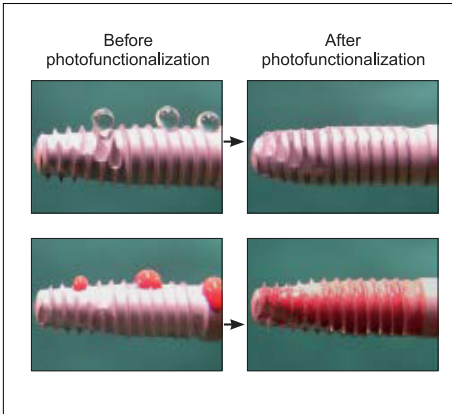


Fig.3-2 Superhydrophilic and superhydrophobic surfaces of dental implants after photofunctionalization. Images show droplets of 3L of double-distilled water and rat blood placed on implant surfaces (left) before and (right) after photofunctionalization. After photofunctionalization, 9μ L of double-distilled water or blood (three droplets of 3μ L each) was sufficient to spread and cover the entire surface of a dental implant.

2) Superhydrophilicity

Implant surface after more than 1 month of surface processing becomes hydrophobic. That is, the contact angle of water on the implant surface is above 60° and, as illustrated in the figures (Fig. 3-1 and 3-2), water dropped onto this surface does not get absorbed but forms droplets. On the other hand, if such surface is irradiated with UV for more than 10

- Graduated from College of Dentistry of Chosun University
- Internship & residency at Chosun University Dental Hospital
- Master's degree from Graduate School of Dentistry of Chosun University
- Educational dental instructor for Korean Association of Maxillofacial Plastic and Reconstructive Surgery

Min-Seok Oh, General Manager, Daejeon Sun Dental Hospital

- Specialist in oral maxillofacial surgery
- General manager of education and training at Sun Dental Hospital
- Editor of Journal of Korean Association of Oral and Maxillofacial Surgeons
- Liaison director of the Daejeon Bureau of the Korean Association of Oral and Maxillofacial Surgeons



minutes, it becomes superhydrophilic and the contact angle becomes close to 0° at which it is possible to observe that water dropped on the surface is absorbed immediately into the surface. This signifies that, at the time of embedding the implant, it is possible to induce quick and firm osseointegration by increasing adsorption of protein involved in osteogenesis by absorbing blood quickly even if bone graft is necessary due to large defect in the area of embedding of implant as well as quick wetting of blood, (Ultraviolet Photofunctionalization of Titanium Implants / Takahiro Ogawa, 2014)

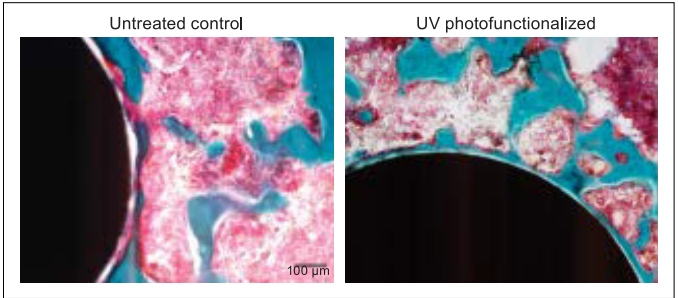


Fig.4 Evidence of increased peri-implant bone generation promoted by UV function-alization. These histologic images show peri-implant tissue at 2 weeks postimplantation in a rat femur model with and without UV treatment (Goldner trichrome).

4) Enhancement of usefulness of short implants

Short implant has excellent level of utilization since it can lower the risks of complications following the minimally invasive procedure and surgery, and since it is possible to anticipate reduction in treatment period and cost by avoiding the need for treatment prior to the implant procedure such as maxillary sinus augmentation and bone augmentation, etc. However, there is limitation in clinical application due to the limitations in the strength of integration between the implant and bone due to its small surface area. However, it had been reported that short implant irradiated with UV displayed synostosis strength equivalent to that of the ordinary implant (with length of more than 10mm) 4 and 8 weeks after irradiation, (Success Rate, Healing Time, and Implant Stability of Photofunctionalized Dental Implants_Akiyoshi Funato, etc., 2013)

5) Overcome the limitation of the cases of immediate embedding after tooth extraction

In the case of embedding the implant immediately after tooth extraction, it is very difficult to embed implant and generating bones while there is no bone simultaneously. According to experiments, the bone contact rate was at about 1/3 of the rate for general case if implant is embedded immediately after tooth extraction. However, in the case of UV irradiated implant, it displayed osseointegration strength equivalent to that of general case, thereby displaying results of healing that is 2~3 folds greater than that for implant without UV irradiation. (Success Rate, Healing Time, and Implant Stability of Photofunctionalized Dental Implants_Akiyoshi Funato, etc., 2013)

6) Shortening the healing time

According to experiments, implant irradiated with UV ray for 15 minutes not only displayed enhancement of its hydrophilicity and blood-friendliness but also reduction in the atomic mass of hydrocarbon on the surface. Moreover, in spite of the fact that more than 90% of the all the cases were difficult cases needing stepwise or simultaneous surgery, photofunctionalized implant through UV irradiation displayed high success rate of 97.6%. The time taken for loading was 3.2 months, which is a substantial reduction in comparison to that of the control group at 6.5 months (Fig. 5). (Success Rate, Healing Time, and Implant Stability of Photofunctionalized Dental Implants_Akiyoshi Funato, etc., 2013)

7) Suppression of inflammation around the implant

Although implant has established itself as a predictable and successful treatment method to solve the loss of tooth, complications due to aesthetic, biological and technical factors have been reported. Among

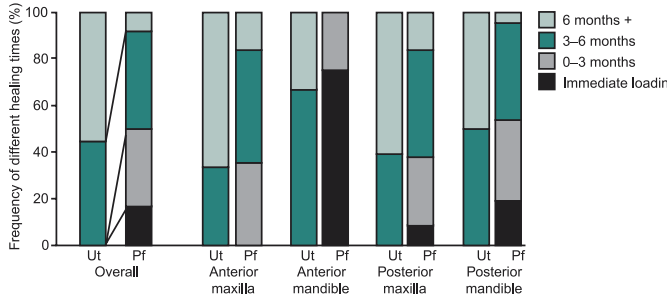


Fig.5 The distribution of specific healing times before functional loading of untreated and photofunctionalized implants. Ut: Untreated implants, Pf: photofunctionalized implants.

these, there is particularly high rate of manifestation of inflammation around the implant. According to experiments, it has been reported that inflammation around the implant occurred in approximately 19~56% of the patients. In the experiment using fully grown dogs, the bone absorption rate around the UV irradiated implant was lower than the bone absorption rate around the implant not irradiated with UV as the results of measurement of bone absorption rate through clinical test, radiological imaging and CT after 90 and 180 days of implant embedding (Fig. 6). Moreover, when the tissue slices are observed histologically, implant without UV irradiation displayed failure in attachment of bones or partial destruction on the interface between the bone and implant. In contrast, there was no observation of bone absorption in the top portion of the UV irradiated implant and it could be observed that interface between the bone and the implant was maintained. (Fig. 7) Resultantly, UV irradiation appears to suppress the progress of inflammation around the implant. (Effect of Ultraviolet Irradiation of the Implant Surface on Progression of Perimplantitis-A Pilot Study in Dogs_Katsuhiko Kimoto, etc., 2016)

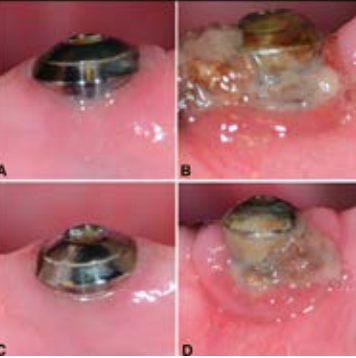


Fig.6 Intraoral photographs. A, Non-UV group after 90 days, (B) UV group after 90 days, (C) non-UV group after 180 days (90 days after dental floss application), and (D) UV group after 180 days (90 days after dental floss application).

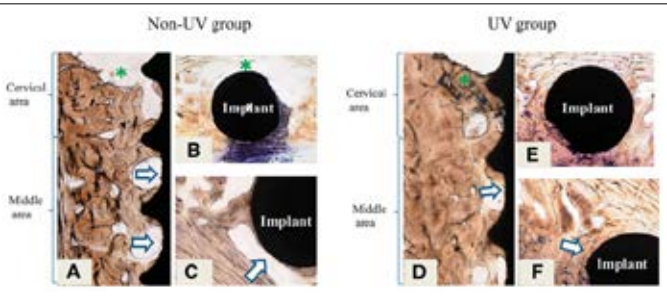


Fig.7 Light microscopic histological images (after 180 days). The grind samples were stained by methylene blue and examined under a light microscope. A, Cervical and middle areas of non-UV-irradiated implant at sagittal section, B, Cervical area of the non-UV-irradiated implant at horizontal section, C, Middle area of the non-UV-irradiated implant at horizontal section, D, Cervical and middle areas of UV-irradiated implant at sagittal section, E, Cervical area of the UV-irradiated implant at horizontal section, F, Middle area of the UV-irradiated implant at horizontal section.

Overcome the Limitation in Surface Processing of Implant! UV Irradiation

I. Literature review on UV irradiated implant / II. Clinical difference between SLA surface finishing and UV irradiated implant / III. Utilization of UV irradiated implant in difficult case / IV. Utilization of UV implant in guide procedure

II. Clinical difference between SLA surface finishing and UV irradiated implant

In the last issue, it was confirmed that biologic aging phenomenon that hinder the binding of bone and implant occurs due to organic matters such as hydrocarbon in the air even for the Sandblasted with large grit and acid etched (SLA) surface finishing, which is evaluated as the most stable and outstanding surface processing technique until now. As a solution, UV irradiation of the implant surface can remove the organic matters from the implant surface and convert the hydrophobic surface into superhydrophilic surface, thereby inducing quick osseointegration by inducing high level of bio-friendliness in the mutual interaction between the implant and the bone generation factors such as protein and cells. In addition, with improvement in the bone to implant contact rate (BIC) for the UV irradiated implant to approximately 2 times higher than that of the SLA surface finishing without UV irradiation, it was conformed that UV irradiation accelerates synostosis process and enhances the extent of osseointegration.

In this issue, the usefulness of UV irradiated implant will be reviewed through comparison of the effects of the SLA surface and UV irradiated implant on osseointegration in actual cellular experiment, animal experiment and in clinical settings to verify the theoretical considerations presented in the previous issue.

II. Clinical difference between SLA surface finishing and UV irradiated implant

[In Vitro Test] Cell proliferation experiment prior to and after UV irradiation (Dental College of Kyunghee University)
Titanium disk with diameter of 10mm was used as a control group after having subjected it to SLA surface treatment. Same titanium disk with SLA surface treatment was further subjected to irradiation with UVC wavelength for 10 minutes for use as the experimental group. Cell proliferation experiment was then conducted by using MC3T3-E1 cell line (mouse osteoblast cells) applied to these disks.

As illustrated in Fig. 1, there was rapid increase in cell proliferation for the disk with UV irradiation in comparison to the control group without UV irradiation since the 3rd day of the commencement of experiment. Based on the results of increase in the quantity of proliferated osteoblast cells, which is an osteogenesis factor, for disk with UV irradiation in comparison to the disk without UV irradiation, it can be presumed that UV irradiation has substantial effect on proliferation of osteoblast cells.

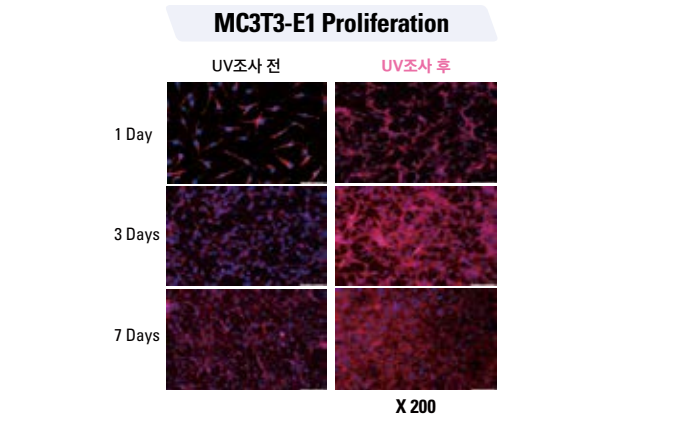


Fig. 1 Cellular proliferation experiment (Dental College of Kyunghee University)

Osteo-mineralization experiment was carried out with the same cell line by applying them onto the titanium disk subjected to SLA surface processing. While SLA surface processed titanium disk displayed approximately 40% increase in osteo-mineralization at the transition time from the 3rd to the 4th week, titanium disk with UV irradiation displayed the effects of approximately 50% increase in osteo-mineralization at the transition time from the 2nd to the 3rd week

(Fig. 2). This is deemed to be the result of increase in the activation of osteoblast by reforming the surface of titanium disk subjected to SLA surface processing into positive (+) charge by removing the residual organic matters such as hydrocarbon by means of UV irradiations, thereby further enhancing the proliferation of osteoblast and osteo-mineralization.

It can be seen that same results are obtained from a diverse range of clinical trials. That is, following the embedding of implant, mechanical binding force is maintained by the existing bone (primary stability) before such binding force is rapidly weakened due to the absorption of the existing bones with passage of time. Meanwhile, the growth of newly generated bones with passage of time increases the binding force with the implant biologically (secondary stability). However, there is a temporary period in which the binding force between the implant and bone drops rapidly (stability dip). In clinical settings, this period of stability dip is evaluated to be in the range of 3~4 weeks after the embedding of the implant.

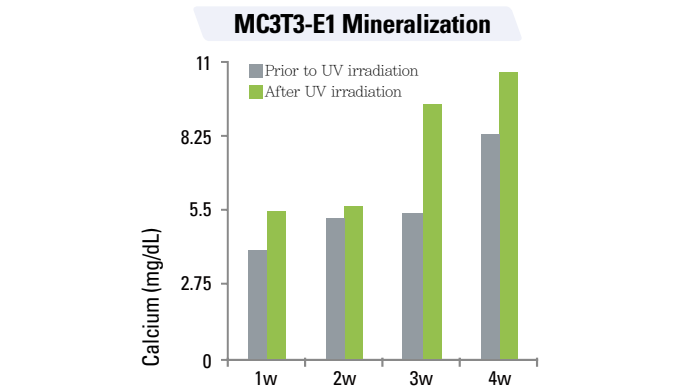


Fig. 2 Osteo-mineralization experiment (Dental College of Kyunghee University)

Therefore, it is deemed possible to prevent failure in the implant embedding and induce quick osseointegration in the early stage by inducing secondary stability at earlier stage by irradiating UV to SLA processed surface.

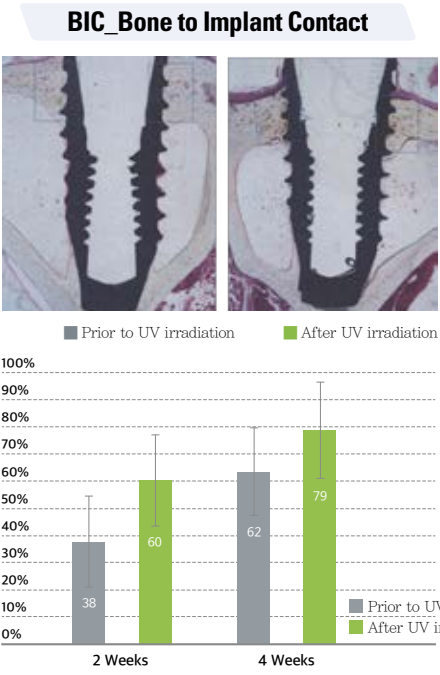
[In Vivo Test] BIC experiment prior to and after UV irradiation (Dental College of Kyunghee University)
The following are the results of animal experiment on the bone to implant contact (BIC) rates of the SLA surface processed implant and UV irradiated (10 minutes) implant (Fig. 3~4). Experiment was executed by embedding 2 each of the SLA implants and UV irradiated implants into the left and right tibia of 3 white rabbits. BIC observations were made at the 2nd and the 4th week of the experiment and there was no death of rabbit during the experiment. As illustrated in Fig. 4, BIC of the UV irradiated implant was measured to be higher than that of the SLA surface processed implant. In particular, BIC for the UV irradiated implant was at a substantially higher level at 80% in comparison to 62% for the SLA surface processed implants at the time of measurement in the 4th week.

Although there was no difference in BIC between the values prior to and after UV irradiation of SLA surface processed implant by more than 2 folds as in the case of the values measured in the experimental rat model of professor Ogawa of UCLA, USA (BIC of 98,2% for UV irradiated implant and BIC of 53% for non-UV irradiated control group at the 4th week of experiment), there nonetheless was approximately 30% higher BIC measured for the UV irradiated implant in comparison to the SLA surface processed implant prior to UV irradiation in this experiment. Therefore, it was possible to confirm that the acceleration of the synostosis process and enhancement of the extent of osseointegration are possible by maintaining synostosis between the bone and implant more advantageously in the latter stage of healing through UV irradiation.

- Graduated from College of Dentistry of Chosun University
- Internship & residency at Chosun University Dental Hospital
- Master's degree from Graduate School of Dentistry of Chosun University
- Educational dental instructor for Korean Association of Maxillofacial Plastic and Reconstructive Surgery

Min-Seok Oh, General Manager, Daejeon Sun Dental Hospital

- Specialist in oral maxillofacial surgery
- General manager of education and training at Sun Dental Hospital
- Editor of Journal of Korean Association of Oral and Maxillofacial Surgeons
- Liaison director of the Daejeon Bureau of the Korean Association of Oral and Maxillofacial Surgeons



[Clinical case] Overdenture by using 2 mandibular implants

A 66-year old female patient with systemic illnesses including high blood pressure, hyperlipidemia and diabetes, etc. was using her 2nd denture. Having used the denture for 5~6 years, she visited our hospital due to the complaints of the lower denture becoming loose and inconveniences including sticking of food in the gaps of the denture.

The maxillomandibular area was in full edentulous state with severe overall bone loss in the area of embedding of implant (Fig. 5). As such, 2 permanent implants were embedded into #33 and #43 in the mandible and 2 interim implants were embedded into #31 and #41 in the mandible to execute treatment in locator overdenture format.

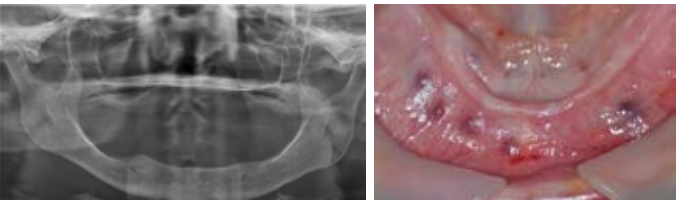


Fig. 5 Panoramic view prior to the procedure and image of the oral cavity (in overall, there is severe bone loss along with poor bone density)

SLA surface processed implant (DIO UFII Ø4,5x11,5mm) was embedded into #33 and UV irradiated implant (DIO UV Active Ø4,5x11,5mm) was embedded into #43 (Fig. 6). UV irradiation was executed for 15 minutes for the implant in Quartz ampoule state by using UV irradiator (DIO UV Activator, Fig. 7).



2 implants (#33 and #43) and 2 interim implants (#31 & #41) were embedded without additional bone graft after having made incision, and the incision was sutured after having attached healing abutment (Fig. 8).

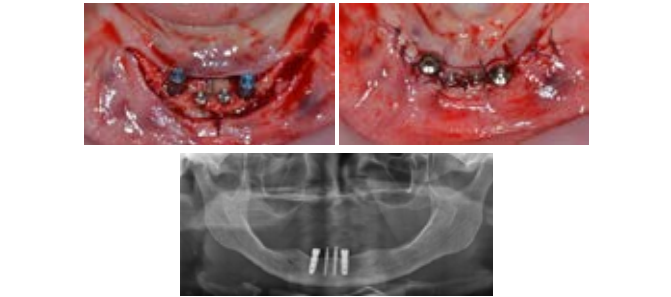


Fig. 8 Panoramic view after embedding of implant and relevant procedures
Implant stability quotient (ISQ) of 68 for #33 and 70 for #43 were measured immediately after embedding of the implant.

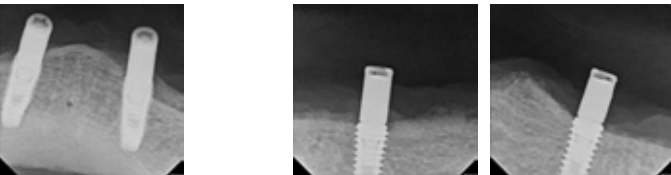
ISQ values are measured through a wide range of formats. While striking format that measures the repulsion velocity and contact time of implant after having struck the implant by using striking device has the advantages of diversified subjects of measurements including natural tooth and implant, etc., it has the limitations including imparting of impact on the implant in the initial stage of embedding with physical force as well as manifestation of different measurement values depending on the location and angle of measurement.

On the other hand, resonance frequency format uses Resonance Frequency Analysis (RFA) to display measurement values that are consistent regardless of the overall conditions of measurement without imparting impact on the implant. As such, it is evaluated as the most scientifically reliable measurement method, and RFA format is used in majority of theses for evaluation of objective data value. In this case, ISQ value was measured by using DIO IDx (Osstell, Sweden, Fig. 9) in the RFA format and continuous measurement data were recorded in the device itself for the corresponding patient for effective utilization in clinical setting.



At 4 weeks after the embedding of implant, ISQ of 72 for #33 (SLA) and 86 for #43 (UV) were measured, thereby illustrating that the ISQ value increased by substantial margin for the UV irradiated implant. Although it was a case of poor bone tissues and insufficient bones, ISQ value was maintained stably. As such, setting of dental prosthetics was executed earlier at the 8th week after the embedding of the implant (Table 1 / Fig. 10).

	1 st op	4week	8week(Loadng)
#33(SLA)	68	72	79
#43(UV)	70	86	87



Overdenture by using locator in the event of insufficient support for dentures due to lost alveolar bones under full edentulous condition is deemed to be an effective clinical treatment method. As the results of comparison of the extent of osseointegration until the time of attachment of dental prosthetics by embedding 2 implants, one with only SLA surface processing and the other with additional UV irradiation, in this case, higher extent of osseointegration could be obtained for the UV irradiated implant.

Overcome the Limitation in Surface Processing of Implant! UV Irradiation

I. Literature review on UV irradiated implant / II. Clinical difference between SLA surface finishing and UV irradiated implant / III. Utilization of UV irradiated implant in difficult case / IV. Utilization of UV implant in guide procedure

Min-Seok Oh, General Manager, Daejeon Sun Dental Hospital



III. Utilization of UV irradiated implant in difficult case

Clinical usefulness of UV irradiated implant was examined in the previous issues. It was confirmed that the extent of short-term osseointegration was more outstanding for UV irradiated implant on the basis of the changes in the ISQ value after having embedded UV irradiated implant and SLA surface processed implant in left to right symmetry in the same patient. In this issue, I will examine whether UV irradiated implant can be applied as an efficient alternative to existing SLA implant on the basis of the results of cases of embedding UV irradiated implant in various difficult cases on the grounds of the theoretical and experimental results dealt with in the previous issues.

III. Utilization of UV irradiated implant in difficult case

[Clinical Case 1]

A 61-year old woman with only high blood pressure (being controlled with drug with good status of control) as the only medical underlying illness has been using full denture for the maxillary teeth. After having experienced failure in the maxillary overdenture implant at a private dental clinic about 1 year ago, she was given the opinion by 3 other dental clinics thereafter. She then visited our hospital as the last resort for assessment of her conditions for application of implants.

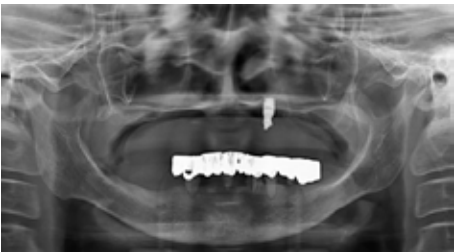

Fig. 1 Panoramic view at the time of initial examination

#23 implant presumed to have been embedded 1 year ago under full edentulous maxillary conditions was in floating state while the 4 remaining mandibular teeth (#31, 33, 34 and 43) were connected with long bridge and were floating as well (Fig. 1).

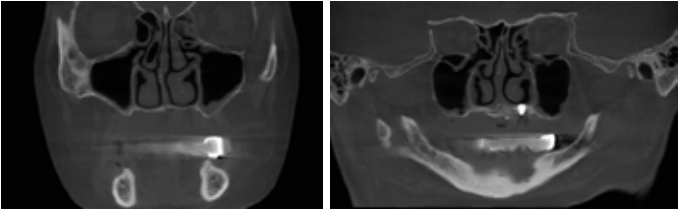


Fig. 2-1 CT coronal view Fig. 2-2 CT panoramic view

Maxillary alveolar ridge under the CT coronal view was completely absorbed in the state of connection without boundary with maxillary palate. The residual bone between the fundus of maxillary sinus and the alveolar ridge was presumed to be about 1mm (Fig. 201). Moreover, the alveolar ridge including basal aspect of nasal cavity was measured in the range of 1~2mm at the time of evaluation of alveolar ridge in canine tooth and premolar tooth under the CT panoramic view (Fig. 2-2).

Treatment plan included removal of the exiting #23 implant, extraction of all residual mandibular teeth, augmentation of the nasal floor, fenestration of lateral wall of maxillary cavity and bone graft accompanied with augmentation first. It was then followed by full fixed type full mouth rehabilitation and establishment of Baroverdenture by embedding 4 implants in the mandible, 6 weeks after the extraction of residual maxillomandibular teeth, augmentation of nasal floor and bone graft accompanying fenestration of lateral wall of maxillary cavity were executed first, which was then followed by embedding implant for overdenture for the mandible (Fig. 3-1 ~ 3-5).



Fig. 3-1 Immediately after incision and augmentation of mucous membrane of nasal floor Fig. 3-2 State of preparation of autologous tooth graft material and BMP

As the bone graft material, the autologous tooth bone graft material obtained by extracting mandibular tooth was mixed with heterogeneous graft material, OCS-H bone, which was then hydrated with solution prepared by mixing 0.25mg of BMP with lidocaine. This was used by coagulation by using Tisseel. The area of surgery was covered with shielding membrane before being sutured.

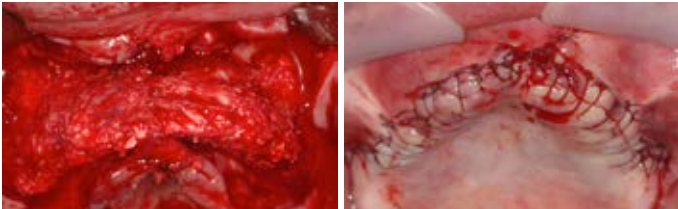


Fig. 3-3 Immediately following completion of bone graft Fig. 3-4 Completion of suture after having applied shielding membrane

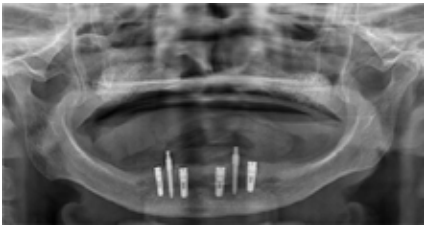


Fig. 3-5 Panoramic view after the procedure

There was no peculiar complication other than edema and pain after the surgery and the area of the bone graft at the nasal floor also displayed findings of normal healing. On the 7th month of the surgery, plans for embedding of maxillary implant was established with UV irradiated implant after having evaluated the conditions of the bones by manufacturing surgical stent. In the case of full maxillary edentulous condition, navigation stent was produced for application after having secured bone anchor on the palatal and buccal aspects. In my case, I used general surgical stent produced since there were cases in which unexpected error occurred at the time of embedding due to failure to obtain definitive support by bone anchor. Fair state of osteogenesis was confirmed under CT after the procedure (Fig. 4-1 ~ 4-3).

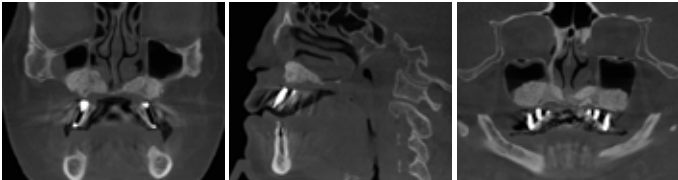


Fig. 4-1 CT coronal view Fig. 4-2 CT cephalic view Fig. 4-3 CT panoramic view after bone graft

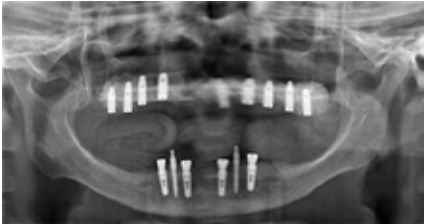

Fig. 5 Panoramic view after having embedded implant

- Graduated from College of Dentistry of Chosun University
- Internship & residency at Chosun University Dental Hospital
- Master's degree from Graduate School of Dentistry of Chosun University
- Educational dental instructor for Korean Association of Maxillofacial Plastic and Reconstructive Surgery

- Specialist in oral maxillofacial surgery
- General manager of education and training at Sun Dental Hospital
- Editor of Journal of Korean Association of Oral and Maxillofacial Surgeons
- Liaison director of the Daejeon Bureau of the Korean Association of Oral and Maxillofacial Surgeons

치식 No.	Imp. Size	Bone Density	식립 Torque	1 ST OP	ISQ 4Week	8Week
#16	DIO UV ø 4.5×10mm	D3	31N	66	75	81
#15	DIO UV ø 4.0×11.5mm	D3	32N	68	75	80
#14	DIO UV ø 4.0×11.5mm	D3	35N	70	77	83
#13	DIO UV ø 4.0×10mm	D3	33N	68	75	81
#21	DIO UV ø 3.3×11.5mm	D3	28N	65	72	78
#23	DIO UV ø 4.0×10mm	D3	33N	67	74	80
#24	DIO UV ø 4.0×10mm	D3	32N	67	75	82
#25	DIO UV ø 4.0×11.5mm	D3	33N	68	74	80
#26	DIO UV ø 4.5×10mm	D3	30N	66	72	79

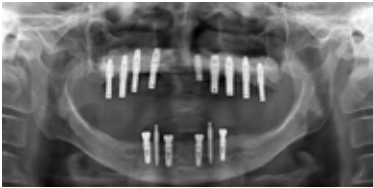


Fig. 6 Panoramic view after the 2nd surgery

After having executed delayed bone graft for reconstruction of fixation type implant in the case that displayed prolonged period of use of full denture for more than 20 years and severe absorption of alveolar ridge, it is presumed that the 1st ossification progressed after 6 or 7 months. Under the situation in which the stability of the area of bone graft cannot be 100% guaranteed, it is deemed that the clinical results would be fair if quick osseointegration can be achieved in early stage through the use of UV irradiated implant.

[Clinical Case 2]

A 69-year old woman with past history of stent surgery due to hyperlipidemia, high blood pressure, osteoporosis and myocardial infarction, and history of having undergone radiation therapy and chemical drug therapy on the lower portion of cervical region and thorax due to breast cancer visited our hospital for the purpose of the prosthetic restoration by using implant for 4 maxillary incisors. Although she was undergoing regular medical examination with determination of full remission of breast cancer as the result of collaborated examination with relevant medical department, she was continuing to take statin to treat her hyperlipidemia and was asked to stop taking this drug. Due to her osteoporosis, it was decided that surgical procedure will be executed after having waited 4 months of drug holidays and cessation of administration of injection drug after having executed total of 5 Bisphosphonate injection therapies at the interval of 3 months. She was allowed to continue to take aspirin aimed at preventing formation of blood clots in the area of stent surgery. Although the patient was under systemically frail condition, she wanted to have aesthetic restoration of the incisors simultaneously.

At the time of reevaluation at the 5th month after the initial examination, there was display of intermediate level of absorption of alveolar bone for the 4 maxillary incisors. Moreover, the conditions of the alveolar bones at #12 and #22 were found to be fair in comparison to those of #11 and #21. Accordingly, immediate implant embedding was planned for the #12 and #22 after extraction of all 4 incisors (Fig. 1-1 ~ 1-3).

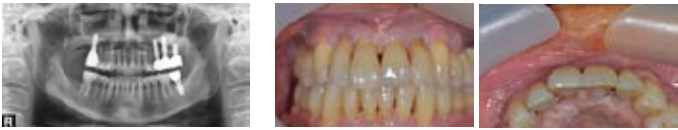

Fig. 1-1 Panoramic view at the time of initial examination Fig. 1-2 & 1-3 Photograph of oral cavity at the time of initial examination

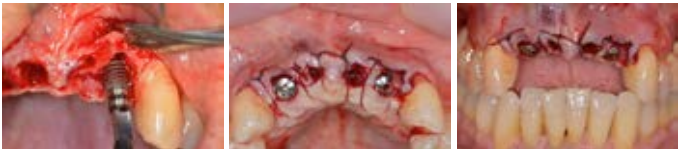

Fig. 2-1 Embedding DIO-UV implant Fig. 2-2 Photograph of oral cavity after the procedure (occlusal surface) Fig. 2-3 Photograph of oral cavity after the procedure (frontal view)

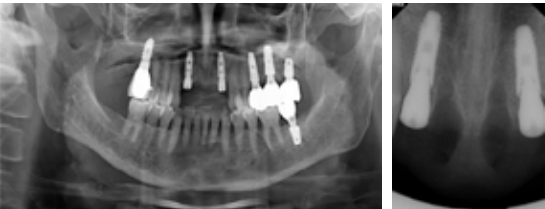


Fig. 2-4 Panoramic view after the procedure

There was no occurrence of complication other than customary edema and pain after the surgery, and confirmation of the photograph of the cross-section of dental root, ISQ measurement and clinical test were executed at 4 and 8 weeks after the surgery (Fig. 3-1)

치식 No.	Imp. Size	Bone Density	식립 Torque	1 ST OP	ISQ 4Week	8Week
#12	DIO UV ø 4.0×11.5mm	D2~D3	35N	70	78	82
#22	DIO UV ø 4.0×11.5mm	D2~D3	40N	72	76	83

At the time of evaluation on the 8th wee, ISQ measured was higher than 80. As such, production of prosthetics was executed after having replaced the healing abutment with ScanBody (Fig. 3-2 and 3-3).

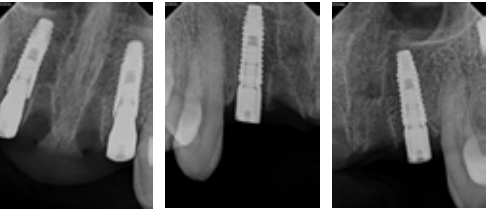


Fig. 3-1 Cross-sectional photograph of dental root at the 4th week

Fig. 3-2 Attachment of #12 ScanBody on the 8th week

Fig. 3-3 Attachment of #22 ScanBody on the 8th week

At the time of F/U after having attached the final prosthetics on the 9th week of the procedure, there was finding of good osseointegration without any particular clinical or radiological findings. Patient was also satisfied with the appearance of gum and prosthetics, etc. (Fig. 4-1 ~ 4-3). Although the margin on the lingual side of the #12 and #22 abutments were exposed slightly due to lack of stability of gum due to the attachment of final prosthetics on the 9th week, it was decided to make determination on re-production of final prosthetics if the gum tissues are stably maintained at the time of examination 6 months thereafter (Fig. 4-4 ~ 4-5).

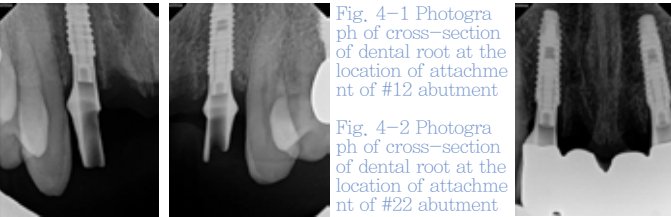


Fig. 4-1 Photograph of cross-section of dental root at the location of attachment of #12 abutment Fig. 4-2 Photograph of cross-section of dental root at the location of attachment of #22 abutment Fig. 4-3 Fig. 4-1 Photograph of cross-section of dental root after the attachment of prosthetics

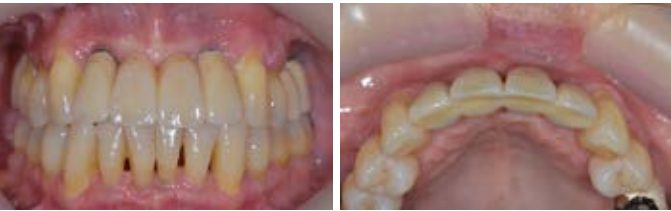

Fig. 4-4 Photograph of attachment of final prosthetics (frontal view) Fig. 4-5 Photograph of attachment of final prosthetics (occlusal surface)

In the event of suffering multiple numbers of systemic illnesses including metabolic disorders, cardiac disorders, osteoporosis and hyperlipidemia, etc., implant therapy needs to be conducted by temporarily stopping the administration of relevant drugs through collaboration with other medical departments. In such case, there is risk of manifestation of systemic medical complications due to cessation of drug administration if the period of implant treatment is prolonged. Therefore, it is necessary to achieve the osseointegration between implant and alveolar bone in as short period of time as possible. In the cases of such patients, UV irradiated implant could be a good clinical alternative.

Overcome the Limitation in Surface Processing of Implant! UV Irradiation

I. Literature review on UV irradiated implant / II. Clinical difference between SLA surface finishing and UV irradiated implant / III. Utilization of UV irradiated implant in difficult case / IV. Utilization of UV implant in guide procedure

Min-Seok Oh, General Manager, Daejeon Sun Dental Hospital



IV. Utilization of UV implant in guide procedure

Reforming change of the implant surface through UV irradiation can induce quick osseointegration and high Bone to Implant Contact (BIC) rate due not only to the increased adsorption of protein but also formation of cell-friendly interface through attachment, proliferation and differentiation of osteoblasts through the following processes: 1) removal of organic matters such as hydrocarbon, etc. from the implant surface, 2) conversion of hydrophobic surface to superhydrophilic surface and 3) induce change in the surface charge from negative to positive.

Therefore, UV irradiated implant is being highlighted as a solution for difficult cases that could only be approached limitedly. Moreover, there is also a demand for assertive application in immediate restoration cases by using surgical guided surgery.

IV. Utilization of UV implant in guide procedure

I believe the Digital Guided Surgery is the hottest issue in the clinical areas at the moment, Digital Guided Surgery is being presented as the solution for extensive utilization and expansion of the treatment domains among the clinicians, Guided procedure, which had been proposed as the solution for cases in which multiple numbers of teeth have been lost, thereby making it difficult to set the reference point for embedding implant, failed to gain support of the dental clinicians due to lower accuracy than expected, prolonged delivery time, higher cost burden and limitation of uses only in specific cases. However, during the recent several years, many of these limitations were solved through advancement of digital imaging technologies (and equipment) and are leading the expansion of the new treatment domains.

[Usefulness of Digital Guided Surgery in clinical settings]

1) Predictability
Precision diagnosis is possible with prediction of the results of the actual procedures through 3D mock surgery on the basis of data obtained through digital imaging devices such as CBCT and oral scanner, etc. As such, it is possible to increase the success rate of implant procedures through considerations for the anatomical structure through the use of digital data rather than simply relying on past experiences. Moreover, it can be the motive force to make communication with the patients more harmonious (Fig. 1).

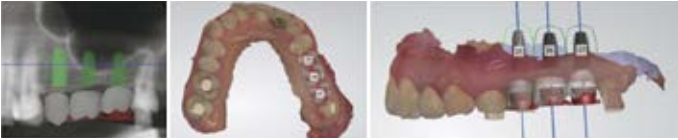


Fig. 1 Data (CT data and intraoral scan data) and mock surgery through digital imaging device

In addition, it is possible to produce temporary prosthetics in advance through mock procedures and it is possible to substantially improve even the aesthetic aspects by setting the prosthetics immediately after embedding the implant.

2) Reduce prosthetics stress (tow-down format)
The latest software for mock procedures for implementation of Digital Guided Surgery sets the location and size of the lost tooth first as illustrated in Fig. 2 and then setting the location, depth and angle of the implant, thereby resolving the stress arising from the manufacturing and attachment of prosthetics. In the event of not using Digital Guided Surgery, there occasionally is accompanying concern for production, attachment and prolonged use of implant prosthetics due to the unintended results of implant embedding.

3) Shorten time taken for the procedure
Although it needs approximately 1 week additionally for the production of guide in addition to the diagnosis process for implant procedure, it can be easily accommodated by the patient through provision of sufficient explanations and information on the advantages thereof. It is

possible to substantially shorten the time take for the implant procedure simply by omitting the suture process, which takes up the longest time in ordinary implant cases, to certain extent.

4) Increase the satisfaction of the patients
Most importantly, there is no reason to reject it from the viewpoint of the surgeon since the level of consent as well as satisfaction of the patient is high. In general, procedure is conducted with minimal incision, there is substantially less bleeding and swelling, thereby resulting in quicker recovery that leads to high level of satisfaction by the patients.

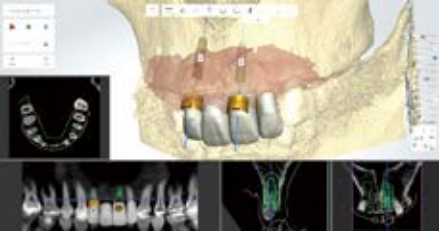

Fig. 2 It is possible to set the position of the implant after having set the prosthetics under Planning Software

[Flapless Surgery]
There had been extensively conflicting opinions on Flap and Flapless surgeries. I believe it is meaningless to try to discern whether these opinions are correct or not since they are based on facts confirmed through experiments by researchers and experiences of clinical surgeons. In fact, I do not prefer Flapless surgery and prefer to execute embedding after having personally checked the bone conditions in most cases. However, it is determined that advantages of Flapless Surgery can be applied usefully in clinical settings since the Digital Guided Surgery in general is conducted in Flapless Surgery format.

1) Prevention of bone absorption
Through various experiments and researches, it has been reported that Flapless Surgery can prevent natural bone absorption. According to Wilderman N, et al., there was absorption of prescribed quantity of marginal bones (average of 0.5mm) after full thickness flap surgery if the Flap is opened. In addition, it reported that there was no such bone absorption in the case of Flapless Surgery, in which the flap was not opened (Fig. 3).

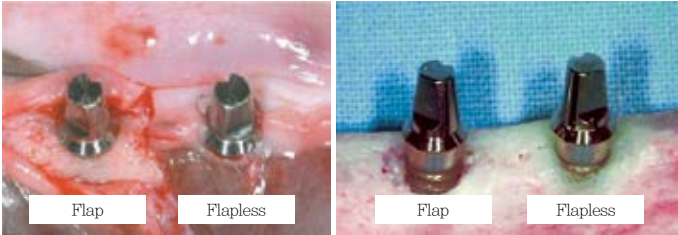


Fig. 3 Absorption of marginal bones after Flap Surgery (left) and Flapless Surgery (right) (animal experiment by professors Byeong-ho Choi and Seung-mi Jeong of Wonju Severance Hospital)

2) Prevention of inflammation around the implant
As the results of histological and clinical examination of the healed surrounding tissues after the implant surgery, it was foreseen that there would be high resistance against inflammation around the implant following healing since deep pockets are not formed in the Flapless Surgery executed without opening the flap (Fig. 4 Professors Byeong-ho Choi and Seung-mi Jeong of Wonju Severance Hospital)

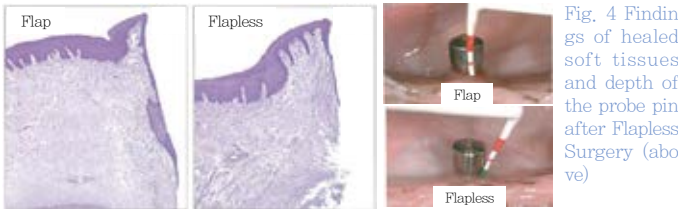


Fig. 4 Findings of healed soft tissues and depth of the probe pin after Flapless Surgery (above)

- Graduated from College of Dentistry of Chosun University
- Internship & residency at Chosun University Dental Hospital
- Master's degree from Graduate School of Dentistry of Chosun University
- Educational dental instructor for Korean Association of Maxillofacial Plastic and Reconstructive Surgery

- Specialist in oral maxillofacial surgery
- General manager of education and training at Sun Dental Hospital
- Editor of Journal of Korean Association of Oral and Maxillofacial Surgeons
- Liaison director of the Daejeon Bureau of the Korean Association of Oral and Maxillofacial Surgeons

It is possible to increase the success rate of implant if embedding of implant that can be predicted through Digital Guided Surgery and if quick osseointegration is accompanied most importantly in immediate restoration cases. Therefore, since diameter and length, etc. of the implant to be embedded have already been decided through analysis prior to the surgery in the Digital Guided Surgery cases, assertive utilization of UV irradiated implant is required as it is possible to reduce the time spent by irradiating the necessary implant with UV ray in advance in time for the surgical time.

[Case]]

A 47-year old male patient without particular past history of diseases visited our hospital with the desire to use fixation type prosthetics by using implant instead of the dentures he has been using. It was planned that among the 5 existing residual teeth, namely, #14, 33, 32, 31 and 43, only #33 and 43 will be left intact with the rest to be extracted along with full mouth rehabilitation for both mandibular and maxillary aspects (Fig. 5)

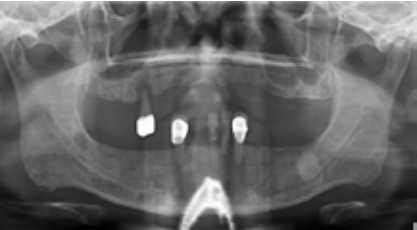

Fig. 5 Panoramic view at the time of initial examination
Full arch was embedded along with augmentation of the maxillary cavity for the maxillary aspect (Fig. 6) while for the mandibular aspect, surgery was executed after having confirmed the location of embedding and type of implant by executing Digital Guided Surgery analysis (Fig. 7-1 ~ 7-5).

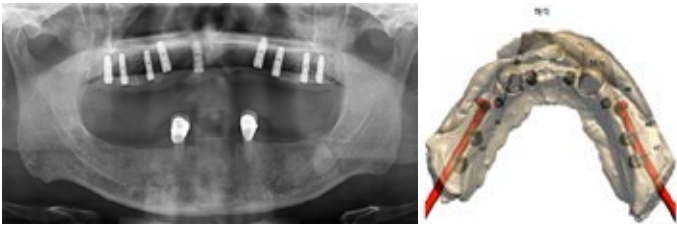


Fig. 6 Panoramic view after the both sinus B,G and 1st maxillary embedding

Information on the implant			
Implant position(FDI)	32	34	36
Manufacturer	DIO	DIO	DIO
Types	UF(II) 3811	UF(II) 4011	UF(II) 5011
Order No.	UF(II) 3811	UF(II) 4011	UF(II) 5011
Length, mm	11.5	11.5	11.5
Diameter(Ø), mm	3.8	4	5
Color	Blue	Red	Green

Information on the implant			
Implant position(FDI)	37	42	44
Manufacturer	DIO	DIO	DIO
Types	UF(II) 5011	UF(II) 4011	UF(II) 4011
Order No.	UF(II) 5011	UF(II) 4011	UF(II) 4011
Length, mm	11.5	11.5	11.5
Diameter(Ø), mm	5	4	4
Color	Green	Red	Red

Fig. 7-1 Digital Guide analysis data

Information on the implant		
Implant position(FDI)	34	
Manufacturer	DIO	
Types	UF(II) 4011	
Order No.	UF(II) 4011	
Length, mm	11.5	
Diameter (Ø), mm	4	
Color	Red	
Safe domain-dental root side distance	2.0	
Safe domain-radiant distance	1.5	

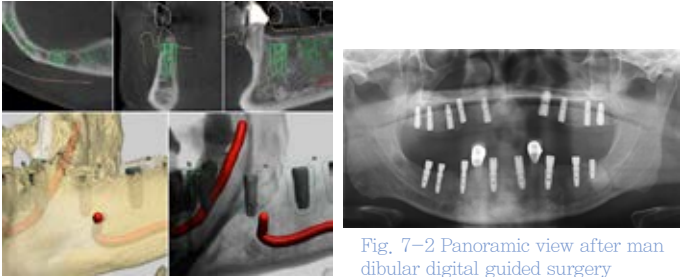


Fig. 7-2 Panoramic view after mandibular digital guided surgery

Fig. 7-2 Digital Guide analysis data

Surgery was conducted for the maxillary aspect after flap elevation due to the issue of bone graft while flapless digital guided surgery was conducted for mandibular aspect. DIO-UV implant was irradiated with UV ray (15 minutes) 20 minutes ahead of the surgery for use (Fig. 8-1 and 8-2).



Fig. 8-1 UV Light irradiator




Fig. 8-2 UV implant

Since there was no particular complication after the procedure, 8th week prosthetics was executed on the basis of the procedure executed for the mandibular aspect and final maxillomandibular prosthetics were completed (Fig. 9-1 and 9-2). In comparison to the general SLA surface implant, the final prosthetics were set about 1 month earlier.

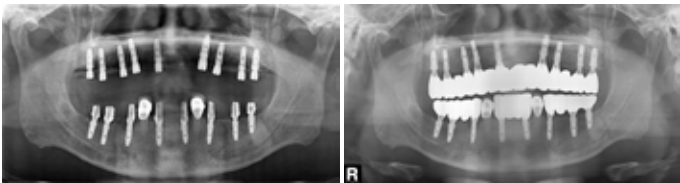


Fig. 9-1 Panoramic view at the state of execution of prosthetics

Fig. 9-1 Panoramic view after the final prosthetics

SLA surface that had been recognized as the most stable and verified implant surface processing method until recently also has certain limitations. The clinical surgeons have the view that these are the innate nature and characteristics of SLA surface processing rather than as limitations of SLA processed surfaces. In conclusion, SLA surface processing is capable of inducing substantially more bio-friendly and quicker osseointegration than how it is felt in clinical setting. However, its functions are simply degraded due to the attachment of organic matters such as hydrocarbon, etc. that interfere with osseointegration onto the implant surface with passage of prescribed period of time after the initial processing of titanium (some products are being distributed by being immersed in solution to prevent contact between the implant surface and air after the processing of titanium). Therefore, it is possible to induce the outstanding bio-friendly properties of SLA surface processing by removing the organic matters attached onto the implant surface immediately prior to the embedding of the implant. Photofunctionalization through UV irradiation is the method used for this purpose. Through this, it would be possible to optimize the original functions of the SLA processed surface including shortening of the time taken for osseointegration healing, fortification of resistance against inflammation around the implant, and improvement of success rate of implant for difficult cases with aged bone or inadequate area of bone contact with implant in the early stage.

